

# A FAMILY WITH HEREDITARY ATAXIA

C.T. TAN

## SUMMARY

*An Indian family with four members having hereditary ataxia was presented. The inheritance was most likely autosomal dominant. The onset was at adult life. The main disability was cerebellar ataxia with pyramidal tract sign found at physical examination. Electroencephalography and nerve conduction study were abnormal in two cases where they were done. The clinical feature correspond to an intermediate form of hereditary ataxia.*

## INTRODUCTION

Since 1863, when Nicholas Friedreich described the Friedreich's Ataxia, many other forms of hereditary ataxia such as hereditary spastic (Sanger Brown Marie), cerebello-olivary atrophy (Holmes type) and olivopontocerebellar atrophy (Dejerine-Thomas type and Menzel type) have been added. It is also well known that patients with intermediate forms of the illness are often seen. An Indian family with four members having an intermediate form of hereditary ataxia is presented.

### Case I (seen in 1980)

The patient was a 31 year old Indian rubber tapper from Port Dickson, Negeri Sembilan. She was the eldest in the family of five siblings. She was well until 5 years before when noted to be slightly unsteady. But this was mild until six months before admission when it progressively became worse. The unsteadiness was mainly with walking but also with use of the hands. Despite that, she was able to continue with her rubber tapping, though slower. There was no history of

alcoholic intake, drug ingestion and head injury. The patient had been staying in Port Dickson all her life. She married her maternal uncle and has two children who are alive and well.

On examination, the mental state was normal. The speech was slightly dysarthric. The gait was broad based and ataxic. There was past pointing with finger nose test and dysdiadochokinesia. The muscle power was normal. Generalised hyper-reflexia occurred with unsustained clonus of both ankles. The plantars were flexor. There was no nystagmus, optic atrophy, sensory abnormality, pes cavus, muscles wasting, and scoliosis noted. No abnormalities were detected with examination of the other systems. Investigations showed normal full blood count and ESR, serum electrolyte, liver function test, urine microscopy, chest x-ray, skull x-ray and ECG. The serum VDRL and TPHA were negative. CSF examination showed normal pressure, normal protein and sugar and no abnormalities in microscopic examination. EEG during wakefulness showed mildly excessive slow waves of mainly theta range over both sides. Nerve conduction studies showed delayed motor and sensory distal latencies for both median nerves from the wrist indicating evidence of underlying neuropathy.

### Case II (seen in 1975)

The patient aged 25 years was a younger brother of Case I. He was second in the family and was employed as a rubber factory worker in Port Dickson, Negeri Sembilan. The patient was well until a year before admission when he developed progressive unsteadiness of gait and dysarthria. There was no history of head trauma or drug intake. He was an occasional drinker of alcohol. The patient was married. His three children were alive and well.

On examination the mental state was normal.

---

C.T. Tan M.B.,B.S. (Melb), M.R.C.P. (U.K.)

Department of Medicine, of Faculty Medicine,  
University of Malaya, Kuala Lumpur, Malaysia.

---

The speech was slurred. His gait was broad based and ataxic with past pointing nose test and dysdiadochokinesia. No muscle wasting was noted. The muscle power was normal. The reflexes were generally brisk with bilateral extensor plantar responses. There was no optic atrophy, nystagmus, scoliosis and pes cavus. Examination of the other systems were normal. Further investigations showed normal full blood count and ESR, serum electrolyte, urine microscopy, chest x-ray and skull x-ray, serum ceruloplasmin level; normal CSF microscopy, protein and glucose level. The serum and CFS VDRL were negative. The patient failed to turn up for follow up. According to his sister, the patient rapidly deteriorated and was confined to bed soon after discharge from hospital. He died a year later at home. No post-mortem was done.

#### **Case III** (seen in 1980)

The patient was a 26 year old third sibling of the family. He has been a tractor driver in an oil palm mill in Jasin, Malacca for more than five years. The patient was well until about five years before admission when he developed progressive ataxia in gait and dysarthria. The progression was particularly rapid at two years before being seen so that on admission, he was confined to bed. There was no history of drug ingestion and alcoholism. The patient was unmarried. On examination, the mental state was normal. The speech was slurred. There was trunkal ataxia as well as unsteadiness in both upper limbs. Mild muscle wasting was noted on the small muscles of the hands. No muscle weakness was noted. The reflexes were hyperactive with bilateral extensor plantar responses. There was no optic atrophy, nystagmus, scoliosis, pes cavus and muscle wasting.

Further investigations showed normal full blood count and ESR, serum electrolyte, urine microscopy and chest x-ray. Wakeful tracing of EEG showed mildly excessive slow waves of delta and theta range over both hemispheres. Nerve conduction study showed delayed motor distal latency for right median nerve from the wrist. The conduction velocity for right lateral popliteal

nerve from knee to ankle was slightly slow. EMG study on right abductor pollices brevis muscle showed excessive amount of broad motor units. The nerve conduction study and EMG was thus indicative of neuropathy.

#### **Case IV** (not seen)

The patient was the father of cases I, II, and III. He was a rubber tapper in Port Dickson, Negeri Sembilan. He was unsteady and dysarthric at the age of 40 years old, was confined to bed at 45 years old and passed away at home when he was 50. He remained mentally normal till death and had no visual difficulties.

#### **Others examined**

The youngest sister of case I, II, and III was unmarried. She was asymptomatic and had hypereflexia of all four limbs only.

The mother of cases I, II and III; the husband of case I, (who was also her maternal uncle), the two children of case I were all examined and found to be normal. The other members of the family refused to come for assessment.

#### **DISCUSSION**

Four members of a family in two generations with three of them seen in University Hospital, Kuala Lumpur were presented. As there was a time span in the development of clinical illness between the father and the children, case III also stayed apart from the rest of the family. A form of hereditary ataxia is the most likely diagnosis.

Among the group of hereditary ataxia, Friedreich's Ataxia is the oldest known as well as the most common. It is also the most "spinal" among the group of illness. Pathologically, the degeneration is mainly at the dorsal half of the spinal cord involving the spinocerebellar tract, posterior column and corticospinal tract. Its most frequent mode of inheritance is autosomal recessive. Clinically, it is characterized by the appearance at the second decade of life of ataxia of extremities and trunk, absence of deep reflexes,

**TABLE I**  
**COMPARISON OF TYPICAL FEATURES OF**  
**VARIOUS TYPES OF HEREDITARY ATAXIA**

<b>Clinical Features</b>	<b>Friedreich's Ataxia</b>	<b>Hereditary Spastic Ataxia [Sanger Brown]</b>	<b>Olivoponto-cerebellar atrophy [Manzel]</b>	<b>Spino-pontine Degeneration</b>
Ataxia in limbs	+	+	+	+
<b>Pyramidal Sign</b>				
Hyperreflexia	0	±	0	±
Extensor plantar	+	+	±	+
<b>Sensory Impairment</b>				
Proprioceptive	+	0	0	±
Touch and Pain	±	0	0	0
<b>Extrapyramidal disorder</b>	0	0	±	0
<b>Peripheral neuropathy</b>	+	0	0	0
<b>Optic Atrophy</b>	±	±	±	0
<b>Nystagmus</b>	+	0	+	+
<b>Kyphoscoliosis</b>	+	0	0	±
<b>Pes cavus</b>	+	0	0	0
<b>Mode of inheritance</b>	recessive	Dominant	Dominant	Dominant
<b>Average age of onset</b>	Puberty	28 years	37 years	30-50 years

+ = common

± = variable

0 = absent

loss of proprioceptive sensation and extensor plantar responses. Pes cavus, scoliosis are present in a high percentage of cases. Dysarthria, muscle atrophy, optic atrophy, cardiac abnormality are not uncommon.

Olivopontocerebellar atrophy, Dejerine-Thomas, Menzel) however is less common. Pathologically it mainly involves the cerebellum and brain stem. The degeneration mainly involves the purkinje's cells, pontine nuclei, the olives, olivopontine connections and transverse pontine fibres. The cases may be sporadic (Dejerine - Thomas type) or familial with autosomal dominant inheritance (Menzel type). Clinically, the patient presents at adult or late middle life with progressive cerebellar ataxia of trunk, extremities and dysarthria. The reflexes are usually normal but loss of knee and ankle jerks or an extensor

plantar response may occur. Dysphagia, oculomotor and facial palsy, extrapyramidal feature with parkinsonism and dementia may occur.

Hereditary spastic ataxia (Sanger Brown and Marie) appears to occupy an intermediate position in the spectrum from the Friedreich's ataxia (predominantly spinal) and olivopontocerebellar atrophy (predominantly cerebellar and brain stem). It is of autosomal dominant inheritance. The main pathological changes occur in the spinal cord with degeneration of the spinocerebellar tract, cell loss in the Clarke's column and degeneration of the posterior column. Cell loss in olivary nucleus, denate nucleus and loss of fibres in cerebellar penduncle are variable. Optic nerve degeneration may occur. Clinically, the patient presents at adult life with progressive trunkal, limb ataxia and dysarthria. Evidence of pyramidal tract involvement is common with normal or

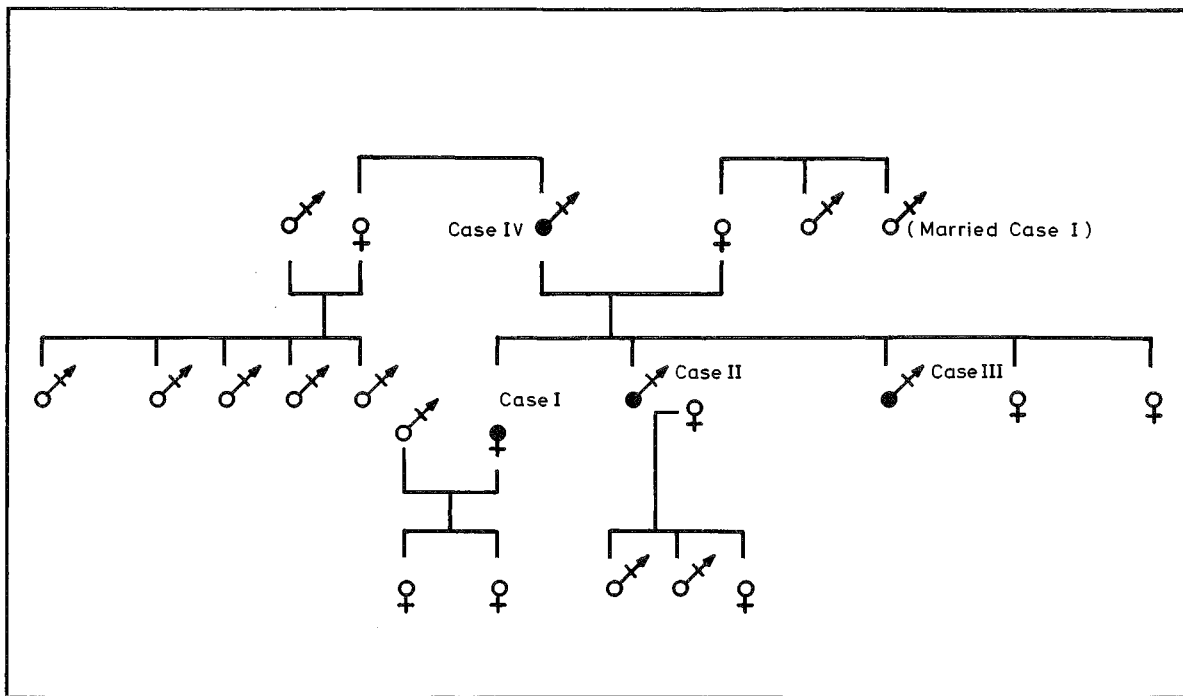


Fig.1. Family Tree With The Affected Members

hyperreflexia and ankle clonus. Visual failure occurs in half of the Sanger Brown family. Nystagmus, ptosis, dysphagia and involuntary movements are variable findings. The duration of illness is often in excess of 15 years.

In 1969, Boller and Segarra reported the first family of "spino-pontine degeneration." Taniguchi and Konigsmark reported another negro family in 1971. Clinically, the picture broadly simulates the hereditary spastic ataxia (Sanger Brown and Marie). The average onset was at middle age. There was progressive trunkal and limb ataxia, dysarthria and nystagmus. Pyramidal tract involvement was common with hyperreflexia and extensor plantar responses in some cases. However, ankle jerks were often absent. Minor sensory abnormalities may occur. Visual failure and mental changes were not part of the picture. Pathologically, there was severe atrophy of the pons with relative sparing of the olives and cerebellum. In the spinal cord, there was degeneration of the posterior column and spino-cerebellar tract.

It is well recognised that the precise pathological features and therefore the clinical symptoms and signs of Friedreich's ataxia differ from one family to another. Further, intermediate forms between the Friedreich's ataxia and Sanger Brown Marie's hereditary spastic ataxia often occur. The term spinocerebellar degeneration was thus introduced to indicate the inseparable relationship between the two forms of illness. The term is particularly used to describe the intermediate form.

In studies where a large number of family members affected over few generations is known (Bell and Carmichael, 1939; Schut, 1950). Friedreich's ataxia, hereditary, spastic ataxia (Sanger Brown) with either exaggerated or diminished deep reflexes as well as hereditary spastic paraplegia has all been seen under one pedigree. There are also cases reported where combined features of Friedreich's ataxia and olivopontocerebellar atrophy are seen clinically and with autopsy. A family with two sisters having olivopontocerebellar degeneration and mother

known to have Friedreich's ataxia has also been reported (Tyrer, 1975). This gives support to uniform theory of the various forms of hereditary ataxia.

With cerebellar ataxia as the main disability and pyramidal tract sign found on physical examination, the clinical picture of our cases most closely resembled the intermediate group of hereditary spastic ataxia (Sanger Brown) and spino-pontine degeneration. The mode of inheritance in our cases was most likely autosomal dominant with the age of presentation as adult at twenties to forty was also consistent with the clinical diagnosis. There were differences as well from the Sanger Brown family and the spino-pontine degeneration. Optic atrophy was not seen in our case and pyramidal signs were constant features when compared with the Sanger Brown family. There was no nystagmus and sensory abnormalities detected in our patient, and the ankle jerk was exaggerated when compared with the families of spino-pontine degeneration.

It is well known that non-specific EEG abnormalities may occur in various forms of hereditary ataxia. In general, the changes become more pronounced as the disease spreads from the spinal cord and cerebellum to the brain stem and cerebral cortex. While these EEG changes have no diagnostic value, it remains valuable in genetic studies in which it can be used to indicate the extent to which the degenerative process is present in members of a family (Liversedge and Emery, 1961; Radermecker, 1977). Non-specific dysrhythmia were found in both our cases where EEG was done. Various authors have reported delay in nerve conduction in patients with Friedreich's ataxia (Dunn, 1973; McCleod, 1970). Electromyography in other forms of hereditary ataxia are not so well studied. Both our cases

where nerve conduction studies were done showed abnormal conduction delay.

## REFERENCES

- Bell, J. and Carmichael, E.A. (1939) On Hereditary Ataxia and Spastic Paraplegia, *Treas. Human Inherit.*, **4**, 141-281.
- Boller, F. and Segarra, J.M. (1969) Spino-pontine degeneration, *European Neurology*, **2**, 356-373.
- Dunn, H.G. (1973) Nerve conduction studies in children with Friedreich's Ataxia and Ataxia Telangiectasia, *Develop. Med. Child Neurol.*, **15**, 324-337.
- Eadie, M.J. (1975) Hereditary Spastic Ataxia. Ed. Vinken and Bruyn, *Handbook of Clinical Neurology*, Vol. 21, North Holland Publishing Company.
- Greenfield, J.G. (1954) The spinocerebellar degeneration, Oxford, Blackwell.
- Liversedge, L.A. and Emery, C. (1961) Electroencephalographic changes in Cerebellar Degenerative lesions, *J. Neurol. Neurosurg Psychiat.*, **24**, 326-330.
- McCleod, J.G. (1970) Electrophysiological and Sural nerve biopsy studies in patients with Friedreich's Ataxia and Charcot-Marie-tooth Disease, *Proc. Austr. Ass. Neurol.*, **7**, 89-95.
- Radermecker, F.J. (1977) Degenerative disease of the nervous system, Ed. Remond, *Handbook of Electroencephalopathy and Clinical Neurophysiology*, Vol. 15A. Elsevier Scientific Publishing Company.
- Schut, J.W. (1950) Hereditary Ataxia. Clinical study through six generations, *Arch. Neurol. Psychiat.* **63**, 535-568.
- Taniguchi, R. and Konigsmark, B.W. (1971) Dominant spino-pontine atrophy. Report of a family through three generations, *Brain* **94**; 349-358.
- Tyrer, J.H. (1975) Friedreich's Ataxia, Ed. Vinken Bruyn. *Handbook of clinical Neurology*, Vol. 21, North Holland Publishing Company.