

# APPROXIMATE ESTIMATION OF THE CONDITION OF DENERVATED MUSCLE BY STUDYING INTENSITY DURATION CURVES

KYAW MINT

HTAY HTAY NWE

R. KANAGASUNTHERAM

## SUMMARY

*Morphological and neuroelectrical changes of the skeletal muscle fibres after various types of injury to the nerve was studied in monkey. The percentage of normal and atrophic muscle fibres after various types of injury to the nerve was compared with the proportion of innervated and denervated muscle as shown by the position of the bend (kink) on the I.D. at corresponding stages. It was found that the pattern and the position of the I.D. curve when considered together only gave an approximate estimation of the proportion of all innervated and denervated muscle fibres as well as the condition of the muscle after denervation.*

## INTRODUCTION

A series of reports on changes in the response of the muscles to electrical stimulus after injury to the nerve has been published since Erb<sup>1</sup> observed that, following denervation, there is an initial increase in

galvanic excitability in which the muscle becomes increasingly sensitive to the anodal closing current (ACC). The minimum amount of current which will excite the muscle for each stimulus and duration may be determined and the results, could be plotted. The curve so obtained, which expresses the relationship of the intensity of a threshold stimulus to its duration, is the intensity duration (I.D.) curve. Though Scott<sup>2</sup> stated that, the effectiveness of a stimulus in producing muscular contraction depends on its intensity and duration, the condition and the amount of contractable muscle fibres after denervation was not included in his consideration. In fact, Bowden and Gutmann,<sup>3</sup> Gutmann and Young<sup>4</sup> and Sunderland and Ray<sup>5</sup> agreed that there is atrophic changes in the skeletal muscle after denervation in which the muscle fibres could have reduced to very narrow strands containing simple series of nuclei if the injury to the nerve is very severe. Therefore, aims of the present investigation is to study the proportion of the normal and atrophic muscle fibres at early and late stages after various degrees of injury to the nerve and to correlate with the pattern of I.D. curve produced at the respective stages. Thus in return, it is also to estimate the approximate condition and the proportion of the normal and atrophic muscle fibres in denervated muscle by studying the I.D. curve in clinical practice.

---

Kyaw Myint, MBBS, MD.  
Department of Anatomy  
Universiti Kebangsaan Malaysia.

Htay Htay Nwe, MBBS,  
Department of Physiology  
Universiti Kebangsaan Malaysia.

Prof. R. Kanagasuntheram, MBBS., Ph. D, FZS.  
Faculty of Medicine  
Jaffna, Sri Lanka.

---

## MATERIALS AND METHODS

The specimens available for the investigation were twelve adult crab-eating monkeys (*Macaca* -

*fascicularis*) of both sexes. Short term study was made in six monkeys at three weeks after the operation and the late stage investigation was done on the remaining six animals at seventy weeks after the operation. The common peroneal nerve was subjected to three types of experimental injury at the knee where the nerve passed around the neck of the fibula. These were crushing the nerve; sectioning the nerve; and removal of the segment of the nerve.

Two monkeys from each group were used for each experiment. At each investigation, motor function of the affected muscles were tested and recorded first with "Orthotron Mark V Stimulator". Tibialis anterior muscle from both operated and normal sides were then removed and investigated for the morphological changes by van Gieson's picric acid - acid fushsin stain modified by Mallory.<sup>6</sup> The results were photomicrographed with "Orthoplan Microscope". Five sections taken from the middle of each denervated and control muscles were projected by a micro-projector from a constant distance with a fixed magnification on to the graph paper and outline of each muscle fibre was drawn. Cross sectional areas of the muscle fibres were than calculated.

## OBSERVATION

Generalized loss of sarcoplasm and a reduction in calibre of the muscle fibres was seen. The average cross sectional area of the fibres was reduced by 36 percent after nerve crush when compared to the normal; it was reduced by 52 percent after nerve section and 56 percent after removal of the nerve segment at the early stage of three weeks after the operation. At the late stage however, the majority of muscle fibres after crush injury were normal in size, with only 6 percent loss in cross sectional area. However, 57 percent and 63 percent reductions in cross sectional areas were seen after nerve section and removal of the nerve segment respectively (Table I).

Moreover, the cross sectional area of each muscle fibre at early and the late stage after various types of injury to the nerve was compared with the mean cross sectional area of a respective normal fibre and were grouped according to their size as follows : the experimental muscle fibres with cross sectional areas which fell within the range of  $\pm 10$  percent of the average normal fibre were regarded as *normal* fibres; fibres which were bigger by more than 10

TABLE I  
PERCENTAGE OF REDUCTION IN SIZE OF WHOLE MUSCLE (TIBIALIS ANTERIOR) AT EARLY AND AT A LATE STAGE AFTER VARIOUS TYPES OF INJURY TO THE COMMON PERONEAL NERVE

TYPE OF INJURY TO THE NERVE	Percentage of reduction in size of whole muscle	
	EARLY	LATE
CRUSHED	36%	6%
SECTIONED	52%	57%
SEGMENTED	56%	63%

percent of the average normal ones were regarded as having undergone *hypertrophy*; fibres which were between 89 percent and 50 percent of the average normal ones were interpreted as having undergone *moderate atrophy*; and fibres which were below 50 percent of the average normal ones were considered as having undergone *severe atrophy*.

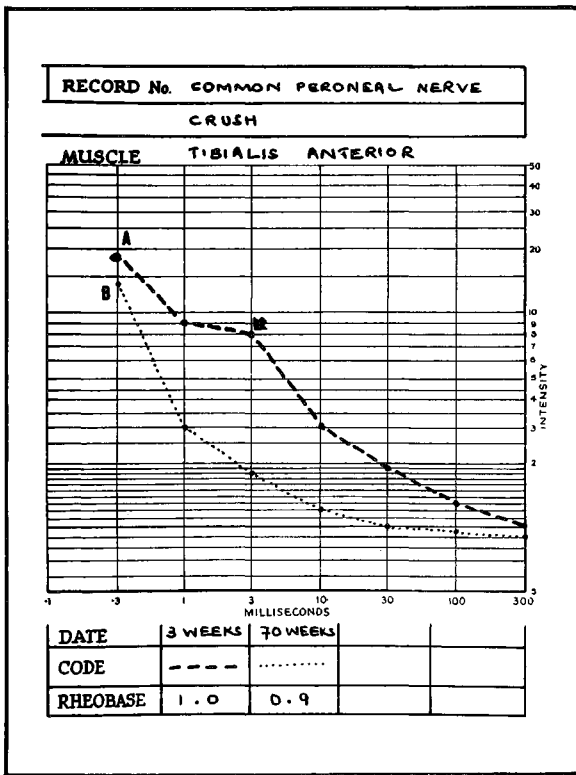
Thus, after nerve crush, 48 percent of the muscle fibres were found to be normal in size with 52 percent showing nerve atrophy at the early stage and 74 percent having normal size with 26 percent exhibiting moderate atrophy at the late stage. After nerve section 12 percent remained normal with 88 percent showing severe atrophy at the early stage while 16 percent exhibited moderate atrophy and 84 percent showed severe atrophy at the late stage. However, after removal of the nerve segment 8 percent of the fibres were found to be normal in size while 92 percent showed severe atrophy at the early stage and 9 percent moderate atrophy with 91 percent severe atrophy at the late stage (Table II).

## DISCUSSION

The percentage of normal and atrophic muscle fibres after injury to the nerve in this investigation was compared with the proportion of innervated and denervated muscle fibres as shown by the position of the bend (kink) on the intensity duration curve at corresponding stages. Hence, three weeks after crush injury to the nerve, the position of the I.D. curve was situated about the middle of the graph, with a prominent bend (kink) near its centre (Fig. I curve A). This indicates that the number of innervated and denervated muscle fibres is almost equal in proportion. This corresponds with the percentage of normal and atrophic muscle fibres of

**TABLE II**  
**PERCENTAGE OF NORMAL, MODERATE ATROPHY AND SEVERE ATROPHY FIBRES OF TIBIALIS ANTERIOR MUSCLE AT EARLY AND AT A LATE STAGE AFTER VARIOUS TYPES OF INJURY TO THE COMMON PERONEAL NERVE**

TYPE OF INJURY TO THE NERVE	EARLY STAGE			LATE STAGE		
	% of fibres in normal range	% of fibres in the range of moderate atrophy	% of fibres in the range of severe atrophy	% of fibres in normal range	% of fibres in the range of moderate atrophy	% of fibres in the range of severe atrophy
CRUSHED	48%	-	52%	74%	26%	-
SECTIONED	12%	-	88%	-	16%	84%
SEGMENTED	8%	-	92%	-	9%	91%



**Fig. 1** The intensity duration curve of tibialis anterior muscle after common peroneal nerve was crushed.

**A)** Three weeks after the injury. The bend (arrow) indicates partial denervation of the muscle. The position of I.D. curve was diagonally across the middle of the graph, with bend near its centre.

**B)** Seventy weeks after the injury. A normal pattern of the curve at left lower part indicates that almost all of the muscle fibres have been reinnervated.

48 percent and 52 percent respectively at this early stage. At seventy weeks after crush injury, the shape and the position of the I.D. curve (Fig. 1 curve B) was almost normal, indicating that most of the muscle fibres were reinnervated i.e. 74 percent of the fibres were in normal range and 26 percent showing moderate atrophy. Thus, at this stage most of the previously atrophied fibres had undergone reinnervation. Therefore, it is presumed that, this could have created enough power during stimulation to produce a curve of normal shape and position as seen in Fig. 1 curve B.

The position of the I.D. curve three weeks after nerve section was in the right upper part (Fig. 2 curve A); the muscle did not respond to stimuli of shorter duration of less than 100 milliseconds, indicating that almost all of the muscle fibres were denervated. Only 12 percent of the fibres were in normal range and 88 percent showed severe atrophy at three weeks after nerve section. This also shows that the rate of atrophy of the muscle fibres after denervation was not the same. Though the majority of the fibres degenerate faster a few fibres degenerate at a slower rate. This slowly degenerating 12 percent of the fibres which still retained the normal size in this case seems unlikely to have enough power to give a contraction to a stimulus of less than 100 milliseconds. The position of the I.D. curve at 70 weeks after nerve section (Fig. 2 curve B) though shifted towards the left when compared to the earlier one, still remained on the right side of the graph. Moreover, the position of the bend (kink) remained on the left upper part of the curve. These findings together indicate that though there was reinnervation, the proportion of

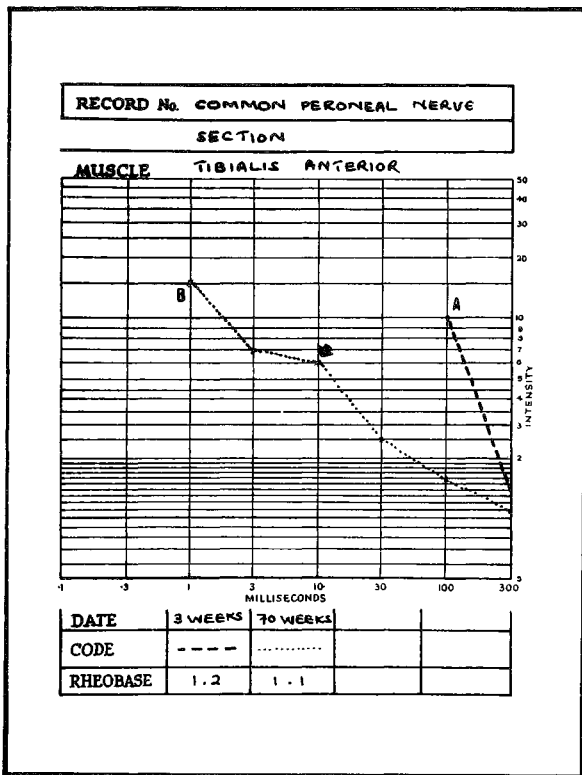


Fig. 2 The intensity duration curve of tibialis anterior muscle after common peroneal nerve was sectioned.

- A) Three weeks after the injury. No contraction of the muscle with stimuli of duration shorter than 100 milliseconds, indicates that almost all of the muscle fibres were denervated.
- B) Seventy weeks after the injury. The position of the curve shifted towards left and bend (arrow) around the middle of the graph indicate partial reinnervation of the muscle.

reinnervated muscle fibres was very much less than those that were denervated. When the percentage of fibre size was observed at this stage, 16 percent of the fibres showed moderate atrophy and 84 percent exhibited severe atrophy.

Similar to nerve section, I.D. curve after removal of the nerve segment (Fig.3 curve A) did not respond to the stimuli with the duration shorter than 100 milliseconds at the early stage. This indicates a total denervation of the muscle fibres. Ninety-two percent of severe atrophic fibres and eighty percent undergoing atrophy but which still retained the normal size in this stage might not be strong enough to give a contraction with an impulse of less than 100 milliseconds. Seventy weeks after removal of the nerve segment, the position of

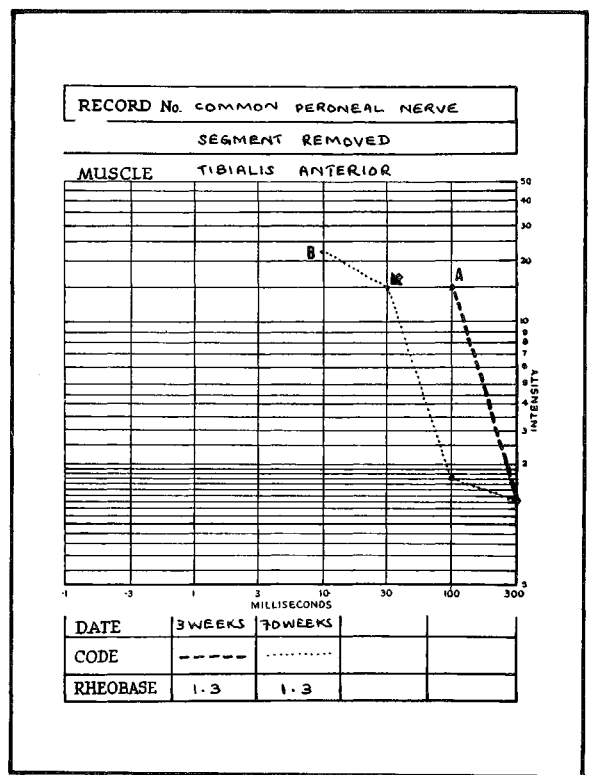


Fig. 3 The intensity duration curve of tibialis anterior muscle after a segment of common peroneal nerve was removed.

- A) Three weeks after the injury. No contraction of the muscle was seen with stimuli of duration shorter than 100 milliseconds.
- B) Seventy weeks after the injury. The position of the bend (arrow) on the upper part together with slight shift of curve towards left indicate that, the muscle is partially reinnervated. Denervated muscle fibres are more than the innervated ones.

the curve remained on the right upper part with the bend at its upper end (Fig. 3 curve B). At this stage the percentage of muscle fibres showing moderate atrophy was nine percent and the remaining 91 percent showed severe atrophy. Chor *et. al.*,<sup>7</sup> Weiss and Edds<sup>8</sup> and Sunderland and Ray<sup>5</sup> demonstrated that there is a rapid initial atrophy of the striated muscle after denervation. However, this process becomes slower as it reaches the relative state of stability at the late stage, which varies from animal to animal. In the present investigation, therefore, the state of stability for the process of atrophy might have been passed and reinnervation might have been started at the late stage after

various types of injury to the nerve, as it shows a reduction in the percentage of severe atrophied fibres when compared to the early stage.

## ACKNOWLEDGEMENT

We wish to thank most sincerely Mrs. Sothi, Tutor, School of Physiotherapy, General Hospital, Kuala Lumpur, for her invaluable advice in this study of electrical reaction of the muscle; Encik Mohd. Hashim bin Abdul Rahman and Encik Peter Thomas Gomes of Anatomy Department, University Kebangsaan Malaysia for their technical assistance.

## REFERENCES

- <sup>1</sup> Erb W (1868). Zur Pathologie und pathologischen Anatomie peripherischen paralyse. *Dt. Arch. Klin. Med.* 4, 535. (Cited by Sunderland and Ray (1950).
- <sup>2</sup> Scot C M (1975) Claton's electrotherapy and actinotherapy. Bailliere Tindall, London. Chapter 13.
- <sup>3</sup> Bowden R E M and Guttmann E (1944) Denervation and re-innervation of human voluntary muscle. *Brain*, 67, 273-282.
- <sup>4</sup> Guttmann E and Young J Z (1944). The re-innervation of muscle after various periods of atrophy. *J. Anat.*, 78, 15-43.
- <sup>5</sup> Sunderland S and Ray L J (1950). Degeneration changes in mammalian striated muscle. *J. Neurol. Neurosurg. Psychiat.*, 13, 159-177.
- <sup>6</sup> Mallory F B (1938). Pathological Technique, Philadelphia, W B Saunders Company, pp. 76-77.
- <sup>7</sup> Chor H, Dolkart R E and Davenport H A (1939). Chemical and histochemical changes in denervated skeletal muscle of the monkey and cat. *Amer. J. Physiol.* 118, 580-587.
- <sup>8</sup> Weiss P and Edds M V (1946) Spontaneous recovery of muscle following partial denervation. *Amer. J. Physiol.*, 145, 587-607.