

# Primary osteogenic sarcoma of spine in a 12 year old boy — a case report

B.A Kareem<sup>1</sup>, MBBS, MS  
*Lecturer*

Hla Myint<sup>4</sup>, MBBS, MRCPATH  
*Lecturer*

Wan Ariffin Abdullah<sup>2</sup>, MBBS, MRCP  
*Lecturer*

Sengupta S<sup>3</sup>, MBBS, FRCSEd  
*Associate Professor*

Zahary Mohd. Kassim<sup>3</sup>, MD, MMed  
*Lecturer*

*Department of Orthopaedics<sup>1</sup>, Paediatrics<sup>2</sup>, Radiology<sup>3</sup> and Pathology<sup>4</sup>,  
Hospital Universiti Sains Malaysia, Kubang Kerian, Kelantan  
Department of Orthopaedics<sup>5</sup>, University Hospital, Kuala Lumpur.*

## Summary

A case of primary osteogenic sarcoma of the lumbar spine in a child is reported and the difficulties in diagnosis and management are discussed.

*Key words:* Lumbar spine, osteogenic sarcoma, bone tumour.

## Introduction

Osteosarcoma is the commonest bone tumour. Its peak age of onset is in the second decade and the male to female ratio is 3:2. Overall, 75% of cases arise in the long bones, usually at the metaphysis.<sup>1</sup> Primary osteogenic sarcoma of the spine is a rare tumour accounting for only 0.85% to 2% of all primary osteogenic sarcomas. The majority of the reported cases were in vertebrae affected by Paget's disease or following radiation exposure.<sup>2</sup> In a recent review of 209 bone tumours from University Hospital, Kuala Lumpur over a seven year period, no case of osteogenic sarcoma of spine was reported.<sup>3</sup> In this report we share our experience with regard to the difficulties in diagnosis and management of primary osteogenic sarcoma of the lumbar vertebrae.

**Case Report:** A 12-year old Malay boy was admitted to the Hospital Universiti Sains Malaysia with the chief complaints of a severe low back pain for three weeks and swelling over the back for two weeks. He had a low grade fever on and off. Pain was aggravated by movements and was not relieved by rest.

Physical finding revealed, a moderately built boy with obvious distress from low back pain and localised tenderness over L3, L4 and L5 region. All movements of lumbar spine were restricted. Slight weakness of quadriceps and extensor hallucis longus on left leg was noted. Investigations revealed alkaline phosphatase, calcium and phosphate levels to be within normal limits and ESR of 83 mm/hour. Mantoux test and sputum for AFB were negative. X-ray of lumbar vertebrae showed osteolytic lesion in the body without narrowing of the inter vertebral disc space of L5. (Fig. 1) Chest x-ray was normal. Aspiration of the paraspinal swelling failed to draw any fluid.

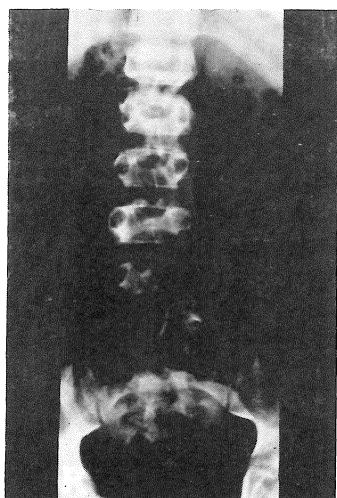


Fig. 1A: A-P view of lumbo-sacral vertebra showing the lesion.

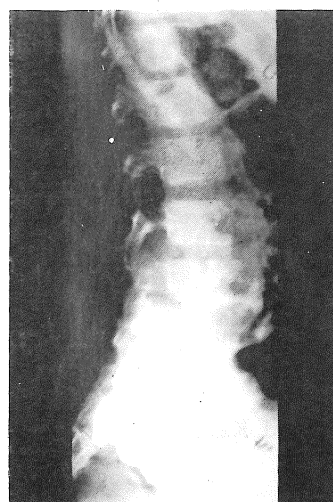


Fig. 1B: Lateral view of lumbo-sacral vertebra showing the lesion.

CT Scan of the lumbar region showed extensive destruction of body of L5 vertebrae and posterior complex. The spinal cord was displaced anteriorly by the intraspinal tumour mass.

Posterior decompression stabilization using Harrington rods and complete resection of the tumour mass through retro peritoneal approach was performed on this patient. The defect was filled with iliac bone graft. Intra operatively the tumour mass was found to be non capsulated, infiltrating into the surrounding muscles and haemorrhagic. Histopathological diagnosis of osteogenic sarcoma was made. (Fig. 2). The patient was put on chemotherapy as per Memorial Sloan-Kettering T7 protocol given below:

---

I/V. Vincristine  $1.5 \text{ mg/m}^2$  on day

I/V. Methotrexate  $250 \text{ mg/kg}$  on day 2

I/V. Adriamycin  $60 \text{ mg/m}^2$  on day 15

I/V. Cyclophosphamide  $400 \text{ mg/kg}$  on day 24

---

Six courses of chemotherapy was given to the patient after total resection of the tumour mass. For last 10 months he has been in continuous complete remission.

A CAT Scan of the lumbar spine showed no evidence of recurrence. The patient is still under follow up.

## Discussion

In under developed and developing countries T.B spine is still a common disease. Some of the tumour or tumour like conditions arising in the vertebral column are osteoid sarcoma, aneurysmal bone cyst, haemangioma, giant cell tumour etc.

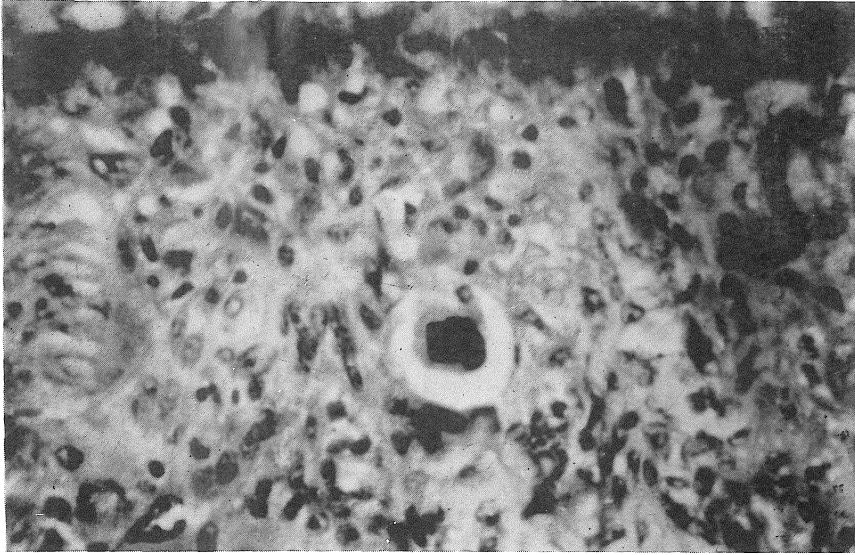


Figure 2: Histology of the resected tumour mass.

From Mayo Clinic out of 1122 patients with primary osteosarcoma of bone from 1909–1980 only 27 cases were reported as primary osteogenic sarcoma of spine of which seven cases were due to post radiation after a period of 2.75 to 31 years. Sacrum was the commonest site followed by lumbar and cervical vertebrae. In this series the youngest patient was a 11-year old female. Most of the patients were in second and third decade.<sup>4</sup> Tumours of the vertebral body usually present early with signs of cord compression as seen in this case.

Needle biopsy is a valuable tool for diagnosis – but has the theoretical risk of tumour dissemination along biopsy tract and also give inferior tissue material compared to open biopsy. Because of this reason and in the presence of features of cord impression an open biopsy was performed.

Over the last one decade we have witnessed a major advance in chemotherapy of primary osteogenic sarcoma. The chemotherapy protocol (T7) used in this patient has shown good results. In one study the continuous remission rate was more than 80% at 30 months.<sup>5</sup> Radiotherapy thought to be a useful adjunct has proven non beneficial, particularly in resectable tumour.<sup>1</sup>

## References

1. Souhami RL. Management of primary malignant bone tumour. *Hospital Update* 1987; 13: 997–1009.
2. Kenneth W Barwick, Andrew G. Huros and Julius Smith. Primary Osteogenic Sarcoma of the Vertebral Column. *Cancer* 1980; 46: 595–604.
3. Peh SC, Cheah PL and Sengupta S: The pathology of tumour and “tumour-like” lesions of bone in the University Hospital, Kuala Lumpur. *Malaysian J Pathol* 1988; 10: 45–50.
4. Thomas C Shiyes, David C Dahlin, Franklin H Sim, Douglas J Pritchard and John D Earle: Osteosarcoma of the spine. *J Bone and Joint Surg* 1986; 68: 660–668.
5. K Winkler, G Beron, K Kotz et al. Neoadjuvant chemotherapy for osteogenic sarcoma: Results of a co-operative German/Australian Study. *J Clin Oncol* 1984; 2: 617–623.