

# Cervical Sympathetic Schwannoma Simulating a Thyroid Nodule

M Rohaizak, FRCS, F A Meah, FRACS

Department of Surgery, Hospital University Kebangsaan Malaysia, Bandar Tun Razak, 56000 Kuala Lumpur

## Summary

Schwannomas are rare tumours arising from peripheral nerve linings. A case of a schwannoma arising from the cervical sympathetic chain is presented. The clinical presentation was that of a right solitary thyroid nodule. Intra-operatively, a 3 x 3 cm encapsulated lesion was seen arising posterior to the vagus nerve and attached to the cervical sympathetic trunk. The lesion was excised together with part of the nerve. Post-operatively, the patient developed Horner's syndrome that persisted. Until 2000, less than 50 cases of cervical sympathetic schwannoma have been described in the English literature. A brief description of the pathology, presentation, diagnosis and treatment of this condition is presented.

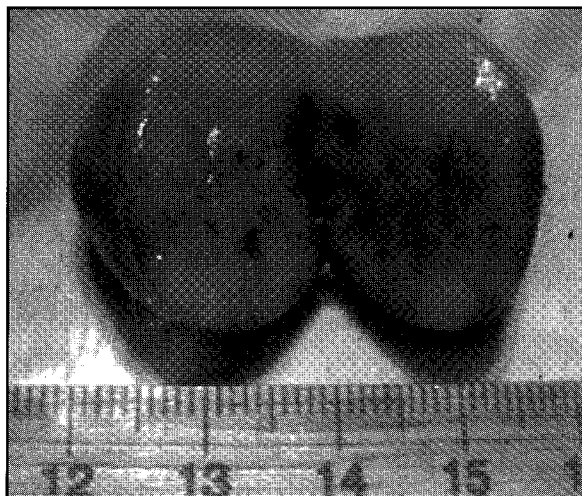
**Key Words:** Schwannoma, Sympathetic trunk, Cervical

## Introduction

Schwannomas are rare benign tumours arising from the peripheral nerve linings. Typically they are slow growing and mostly sporadic. They constitute 5% of all soft tissue tumours and 25-45% of extra-cranial schwannoma occurs in the neck. Most tumours are asymptomatic and exact determination of the nerve origin is difficult until surgery. Treatment involves enucleation of the tumour or excision with part of the nerve. Recurrence of the tumour is rare.

## Case Report

A 24 years old Chinese lady presented to our clinic with a painless, slowly enlarging right sided neck swelling since early childhood. There was no neurological or compressive symptoms. Clinical examination revealed a 3 x 3 cm hard,



**Fig. 1: Cervical Schwannoma**

rounded mass at the upper pole of the right lobe of the thyroid. It was slightly mobile and moved

This article was accepted: 4 March 2002

Corresponding Author: Dr Rohaizak Muhammad, Department of Surgery, Hospital University Kebangsaan Malaysia, Bandar Tun Razak, 56000 Kuala Lumpur

with swallowing. Fine needle aspiration cytology was done twice but inconclusive as no cellular fragments were obtained. At operation, a solid, rounded lesion was seen arising from the cervical sympathetic trunk. There was no invasion to the surrounding structures and the right lobe of thyroid was normal. The lesion was excised together with part of the nerve as the lesion could not be separated from the nerve. Primary nerve repair was not attempted as the defect was too wide apart. The histology showed a well circumscribed and partially encapsulated mass composed of predominantly spindle shaped cells with eosinophilic cytoplasm. In some areas, the nuclei are arranged in parallel row or palisading (Antoni Type A). Post-operatively, the patient developed right Horner's syndrome but discharged well.

## Discussion

Schwannoma of the neck is a rare tumour. It can arise from any peripheral, cranial or autonomic nerve in the neck. It was first described in 1908 by Verocay who named them neurinomas. Since then, various names had been given including neurilemmoma, solitary nerve sheath tumour and perineural fibroblast tumour. The common sites are the facial and vestibulo-cochlear nerves and until end of 1999, less than 40 cases of schwannomas arising from the cervical sympathetic trunk been reported in the English literature<sup>1</sup>.

It is generally well encapsulated and less than 5 cm in diameter but sizes greater than 15 cm have been reported<sup>1</sup>. Microscopically, schwannomas can be divided into 2 main characteristic patterns, the Antoni Type A, composed of cells arranged in a palisading pattern around central acellular, eosinophilic areas known as *Verocay bodies* and Antoni Type B, where the tumour lacks of cellularity and the cells are loosely arranged. The axon of the involved nerve is usually found stretched over the tumour capsule rather than dispersed within its substance. Malignant

transformation of schwannoma is controversial and seldom occurs.

The tumour is normally solitary and presents as a slow growing mass. It can occur at any age but common between the ages of 30 and 70 with an equal sex distribution<sup>1</sup>. It is sporadic but also seen in 90% of neurofibromatosis Type 2 (NF-2 associated schwannoma). The melanotic schwannoma can form part of the Carney complex, which is characterized by spotty skin pigmentation, myxomas, endocrine overactivity, and psammomatous melanotic schwannomas. This is an autosomal dominant trait and the schwannoma normally occurs along the upper gastrointestinal tract and sympathetic chains<sup>2</sup>.

A cervical schwannoma is usually asymptomatic and neurologic findings are usually absent. This makes pre-operative diagnosis very difficult. The existence of Horner's syndrome pre-operatively has only been reported in 6 cases of cervical sympathetic schwannomas<sup>3</sup>. Non-specific symptoms such as pain, tinnitus, hoarseness or voice changes may present in association with a large bulky tumour.

Cervical sympathetic schwannoma can mimic various neck tumours arising from the thyroid, carotids, cervical lymph nodes and congenital remnants such as branchial cyst. A contrast enhancing CT scan and Magnetic Resonance Imaging (T2-weighted image) may show an enhancing lesion of schwannoma, which also can be seen in paragangliomas, lymphomas or vascular tumours. In 20% of cases, the CT scan shows a hypodense area reflecting cystic changes. A fine needle aspiration cytology when successfully done is a safe and effective means of establishing diagnosis<sup>1</sup>.

Operative excision remains the treatment of choice. When the lesion is known pre-operatively as schwannoma, the lesion can be shelled out by opening the capsule to reduce the post-operative functional deficit. If the diagnosis was not made pre-operatively or the nerve trunk cannot be preserved, it may require an excision of a portion

## CASE REPORT

of the nerve. Out of 38 reported cases of cervical sympathetic schwannomas, 76% of patients developed partial or full Horner's syndrome post-operatively. Conley on the other hand reported an excellent functional result in patients with schwannoma who had excision of the nerve with immediate end to end anastomosis or interposition nerve graft<sup>4</sup>. Prognosis of schwannoma is excellent as the tumour only recurs in 5% of cases<sup>3</sup>.

In conclusion cervical sympathetic schwannomas are very rare. They can simulate various lesion in the neck. Pre-operative radiological examination and fine needle aspiration cytology are helpful in the diagnosis. Proper counseling should be made pre-operatively in a suspected schwannoma of the cervical sympathetic chain, as post-operative Horner's syndrome is not uncommon.

---

### References

1. Motimaya A, Arici M. Sympathetic schwannoma: a case report. *Connecticut Medicine* Jul 1999; 63(7): 405-7.
2. Carney JA: Carney complex: The complex of myxomas, spotty pigmentation, endocrine overactivity, and schwannomas. *Semin Dermatol* 1995; 14: 90-8.
3. Ganeson S, Harar RP, Owen RA, Dawkins RS, Prior AJ. Horner's syndrome: a rare presentation of cervical sympathetic chain schwannoma. *J Laryngology & Otology*. May 1997; 111(5): 493-5.
4. Conley J. Neurogenous tumours in the neck. *Arch Otolaryngol* 1955; 61: 167-80.