

# Right Internal Carotid Pseudoaneurysm Mimicking A Retropharyngeal Abscess in a Child

N N A Lee, MMed (Radiology)\*, G Long (FRCR)\*, S Ngai (MBBS)\*, S Sahrir, MS (ENT)\*\*, A Parker (FRCS)\*\*, A C Lamont (FRCR)\*

\*Department of Radiology, School of Medical Sciences, Universiti Sains Malaysia, 16150 Kubang Kerian, Kelantan, Malaysia, \*\*Department of Children's Imaging, \*\*\*Department of Ear, Nose & Throat, Mater Children's Hospital, Raymond Terrace, 4101 South Brisbane, Queensland

## Summary

A 7-year-old girl with tonsillar infection was treated with antibiotics. Two weeks later, there was a right sided neck lump. Computed tomography scans demonstrated a predominantly hypodense right retropharyngeal area with peripheral enhancement and mass effect. There was intense enhancement within the postero-superior aspect of the lesion which was continuous with the right internal carotid artery. Ultrasound demonstrated tapering of the right internal carotid artery. Magnetic resonance imaging and magnetic resonance arteriography showed a right internal carotid artery pseudoaneurysm. Surgical exploration confirmed the finding. This case highlights an unusual presentation of an internal carotid pseudoaneurysm and how imaging provided the diagnosis.

**Key Words:** Pseudoaneurysm, Retropharyngeal mass, Haematoma, Magnetic resonance imaging, Magnetic resonance arteriography

## Case history

A 7-year-old girl presented with a right sided neck lump, associated with sleep apnea, vertigo and vomiting. There was history of tonsillitis two weeks previously which was treated with oral C. Penicillin for a week. Clinically, she was afebrile. Her vital signs were normal. There was no evidence of stridor or hoarseness. Ear, nose and throat examination revealed bilateral tonsillar hypertrophy, more marked on the right. The right tonsillar and peritonsillar areas were congested and there was bulging of the right posterior pillar. The uvula was pushed to the left and the tongue was deviated to the right. Examination of the nose and ears were normal. There was palpable right jugulodigastric node. Eye examination demonstrated bilateral reactive but unequal pupils, the right smaller than the left. Neurological examination was otherwise normal.

A provisional diagnosis of peritonsillar abscess was reached. Throat swabs yielded *Streptococcus pyogenes* which was sensitive to Penicillin, Clindamycin and Cefotaxime. The full blood count showed no evidence of infection. Computed tomography scans of the neck with intravenous contrast enhancement revealed a large right posterolateral 3.0cm by 2.5cm by 1.5cm retropharyngeal mass. Ultrasound of the neck showed the right internal carotid artery tapering gradually as it ascended from the carotid bifurcation and approached the skull base. There was reduced velocity flow in this segment.

A high retropharyngeal abscess was suspected with an associated pseudoaneurysm of the right internal carotid artery. Further imaging with magnetic resonance imaging (MRI) showed a discrete mass within the carotid space which extended into the prevertebral soft

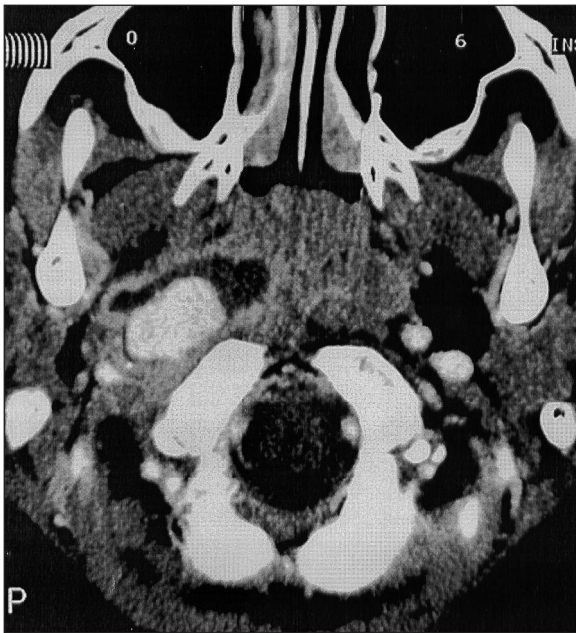
This article was accepted: 17 April 2004

Corresponding Author: Noreen Norfaraheen Lee, Department of Radiology, School of Medical Sciences, Universiti Sains Malaysia, 16150 Kubang Kerian, Kelantan, Malaysia

## CASE REPORT

tissues. The surrounding soft tissue planes were clear. Magnetic resonance angiography (MRA) demonstrated the right internal carotid artery coursed along the posterolateral aspect of the mass, dilated to form a false aneurysm and then tapered towards the skull base. The conclusion from the MRI and MRA studies was of pseudoaneurysm of the right internal carotid artery with associated haematoma rather than an abscess due to the lack of surrounding inflammatory change.

Intravenous antibiotic therapy was commenced with Crystalline Penicillin but the patient deteriorated neurologically. She developed a right 7th cranial nerve palsy manifested with right facial palsy, tongue deviation to the right, ptosis and a small right pupil. Surgical exploration was performed and the lesion was proven to be a pseudoaneurysm of the right internal carotid artery. The aneurysm disintegrated during dissection. No pus was seen.

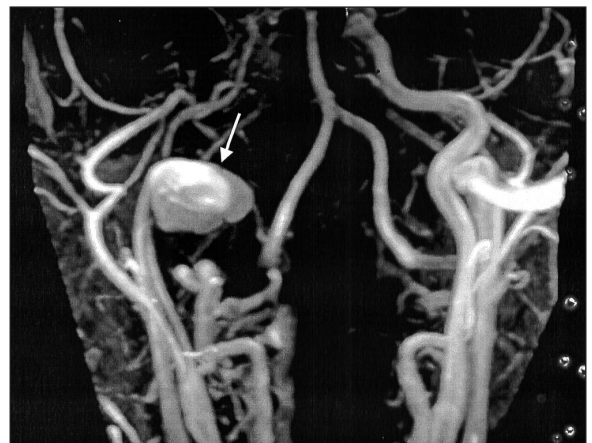

**Fig. 1:** Axial CT image with intravenous contrast enhancement demonstrates a right retropharyngeal low attenuation mass with a thin contrast enhancing wall and a focal area of intense enhancement within the postero-superior aspect of the lesion which appeared to be continuous with the right internal carotid artery.

The patient made a full recovery with no residual neck mass or neurological deficit. One week later, she was discharged home and on follow up after six weeks, she had recovered completely.

## Discussion

Pseudoaneurysms may arise from any artery in the body. In the neck, the internal carotid artery is most commonly involved<sup>1</sup>. Pseudoaneurysms in the neck may be caused by trauma sustained during invasive procedures, penetrating neck injury or infection<sup>1</sup>. Pseudoaneurysms are also seen in intravenous drug abusers. Pseudoaneurysms and deep neck space infection cannot be differentiated clinically as both present with posterior pharyngeal swelling, drooling, neck lump, hoarse voice and stridor<sup>1</sup>. Diagnostic imaging procedures prior to any surgical intervention are essential. Computed tomography (CT) scan is the first line investigation in suspected deep neck infection. CT scan provides a good overall view of the neck and is non-invasive. It also detects early abscess formation and demonstrates the location and extent. The CT characteristics of pseudoaneurysm include loss of fat planes of the carotid artery and intense enhancement of the central portion of the mass located in the course of the carotid artery<sup>2</sup>. Vessel narrowing is a common feature and due either to spasm or inflammation of the vessel wall. The CT characteristics of retropharyngeal abscess include the presence of air interspersed in the



**Fig. 2:** MRA demonstrates the pseudoaneurysm of the right internal carotid artery (arrow)

inflammatory tissues, a distinct enhancing abscess wall and diffuse oedema which shows as a circumscribed area of low attenuation<sup>2</sup>.

Ultrasound has the advantage of being well tolerated, requires no sedation, involves no ionizing radiation and offers good vessel calibre visualization. Doppler studies demonstrate arterial narrowing or dilatation and reliably detect arterial flow<sup>2</sup>. The limitation to ultrasound is the skull base which limits sonographic access. Angiography is useful to confirm arterial involvement, evaluate the collateral circulation and help to strategise the eventual carotid ligation or determine the vessels to be occluded<sup>3</sup>. However, potential complications include haematoma, aneurysm or pseudoaneurysm formation at the puncture site, complications related to sedation or general anaesthesia and infection.

Magnetic Resonance Imaging (MRI) and Magnetic Resonance Arteriography (MRA) are non-invasive, do not use ionizing radiation and have multiplanar imaging capability. Inherent tissue contrast on MRI allows more effectively demonstration than CT of a mass and the nature of its content. MRA demonstrates the feeding vessels and anomalies. MRI easily differentiates between aneurysm, pseudoaneurysm, arteriovenous malformation and haemangioma. The features of pseudoaneurysm are best demonstrated with contrast enhanced T1W images are circumferential wall enhancement and significant narrowing of the vessel lumen. Vessel narrowing is likely to be due to spasm resulting from contiguous inflammation or actual involvement of the wall by the inflammatory arteritis. By comparison, hallmark MRI features of an abscess are wall thickening and marked enhancement.

---

### References

1. Constantides H, Passant C, Waddel AN. Mycotic pseudoaneurysm of common carotid artery mimicking parapharyngeal abscess. *The Journal of Laryngology & Oncology* 2000; 114: 796-97.
2. Glassier CM, Stark JE, Jacobs RF, Mancias P, Leithiser RE. CT and US imaging of retropharyngeal abscess in children. *AJNR* 1992; 13(4): 1191-5.
3. Lueg EA, Awerbuck D, Forte V. Ligation of a mycotic pseudoaneurysm of an extracranial internal carotid artery: A case report. *Int. J. Pediatr. Otorhinolaryngology* 1995; 33(1): 67-74.