

A Combined Case of Macroprolactinoma, Growth Hormone Excess and Graves' Disease

Z Hussein, MRCP*, B Tress**, P G Colman, FRACP***

*Department of Medicine, Hospital Putrajaya, Putrajaya, Presint 7, 62250 Malaysia, **Department of Radiology, The Royal Melbourne Hospital, Parkville, Victoria, Australia, ***Department of Diabetes and Endocrinology, The Royal Melbourne Hospital, Parkville, Victoria, Australia

Summary

Thyrotoxicosis due to Graves' disease is a relatively common endocrine disorder. The occurrence of a prolactinoma with co-secretion of growth hormone (GH) is on the other hand, rare. We report the rare co-existence of Graves' disease in a patient with macroprolactinoma and GH hypersecretion and describe the successful response to medical therapy with dopamine agonist and antithyroid therapy. We hypothesize that hyperprolactinaemia played a role in promoting autoimmune thyroid disease in our patient and that treatment of hyperprolactinaemia may have been important in suppressing autoimmune disease activity in Graves' disease. This case also reflects on the close and complex interactions between thyroid hormones, prolactin (PRL), GH and testosterone (T).

Key Words: Prolactinoma, Hyperprolactinaemia, Graves' disease, Thyroid autoantibodies, Growth hormone, Testosterone

Introduction

Hyperprolactinaemia has been implicated as a modulator in a number of immune-mediated diseases including systemic lupus erythematosus, autoimmune uveitis and autoimmune thyroid disease¹. Dopaminergic agents suppress PRL and have previously been used in clinical trials to treat a number of autoimmune diseases. A few reports have described an association between prolactinomas and Graves' disease and an increased incidence of thyroid autoantibodies among hyperprolactinaemic individuals^{2,3}. We describe the rare and interesting coexistence of Graves' disease in a patient with a macroprolactinoma co-secreting GH.

Case Report

A 32-year-old Chinese Malaysian male patient presented with progressive headache and 15kg weight loss. He had experienced chronic headache for several

years but these had worsened in the 2 months prior to presentation and were often accompanied by vomiting. There was no visual disturbance. The marked weight loss was associated with heat intolerance, reduced energy levels and proximal muscle weakness. There was no reported change in facial features. He had noticed a gradual loss of libido, absent sexual activity over the recent months and was also shaving less frequently. There was no spontaneous galactorrhea. A computerized tomography (CT) scan performed prior to his referral to the hospital showed a pituitary tumor with suprasellar extension.

He weighed 64kg and had a diffuse, firm goitre with no bruit. There was bilateral exophthalmos and lid-lag. He had hyper-reflexia, a fine tremor but no tachycardia. There was onycholysis of the fingernails and mild proximal myopathy but no pretibial myxoedema. Scanty expressible galactorrhea was demonstrated and he had reduced axillary hair and absent trunkal body

This article was accepted: 16 August 2004

Corresponding Author: Zanariah Hussein, Division of Endocrinology, Department of Medicine, Putrajaya Hospital, Presint 7, 62250, Putrajaya, Malaysia

hair. Both testes were soft with volume approximately 12 ml. There were no typical facial features of acromegaly and no visceral organomegaly. Visual fields and visual acuity were normal. Both optic discs were normal. His blood pressure was 120/70mmHg with no postural change.

Serum PRL level was 14660 mu/L (NR 70 - 550), random GH 13.5 mIU/L (NR 0.13-5.0) and IGF-1 3.20 IU/ml (NR 0.34 - 1.42). Mid-morning cortisol was 228 nmol/L and ACTH 8.2 pmol/ml. Serum T was 1.7 nmol/L (NR 7 - 28) with correspondingly low FSH (0.8mU/L) and LH (1.1 mU/L). His free T4 was 58.8 pmol/L (NR 9.0 - 26.0), total T3 5.3 nmol/L (NR 1.1 - 2.7) and TSH <0.04 mU/L (NR 0.1 - 4.0). TSH receptor antibodies were elevated at 19 units (NR -15 to +15), thyroglobulin antibodies 340 IU/L (NR <100) and thyroid peroxidase antibodies 620 IU/L (NR <100). In an oral glucose tolerance test (75g-OGTT) fasting plasma glucose was 4.2 mmol/L, 1-hour plasma glucose 12.4 mmol/L and 2 hours plasma glucose 7.6 mmol/l (impaired glucose tolerance).

An MRI scan demonstrated an enlarged pituitary fossa with a contrast enhancing intrasellar mass, approximately 1.5cm in diameter; the mass had a heterogeneous appearance with an area of poor contrast enhancement on the right suggestive of a cystic component. The pituitary stalk was deviated to the right and there was suprasellar extension with the mass abutting the optic chiasm superiorly (Figure 1). The tumor appeared to partially surround the left intracavernous internal carotid artery but no cavernous

sinus invasion was seen. A Technetium 99 m thyroid scan revealed a moderate and symmetrical enlargement of both lobes with uniform intense tracer uptake of 10% (NR < 4%), consistent with Graves' disease.

The preliminary diagnosis was of a PRL secreting pituitary macroadenoma with co-secretion of GH and hypogonadotrophic hypogonadism. Hypogonadism was more likely secondary to severe hyperprolactinemia rather than part of hypopituitarism due to disruption of anterior pituitary hormones from a macroadenoma as there were no associated deficiencies in GH, thyroid hormone and ACTH-cortisol secretion. However, the most surprising feature was the co-existence of hyperthyroidism secondary to Graves' disease, which initiated presentation.

Cabergoline 0.5mg twice weekly was commenced. Two weeks later, carbimazole 30mg daily was added following review of the results of thyroid autoantibody tests and thyroid scan. There was a prompt response in hyperthyroid symptoms with associated weight gain of 5 kg after 4 weeks of antithyroid treatment and subsequently a total of 17 kg weight gain following 5 months of treatment. Symptoms of headache improved significantly 4 weeks after initiation of Cabergoline and had completely resolved at the fifth month of follow-up. Serial thyroid function tests, serum PRL, GH, IGF-1, FSH, LH and testosterone levels were monitored (Table I). Serum thyroid hormones normalized after 6 weeks of antithyroid treatment and TSH normalized at 5 months. There was a stepwise reduction in PRL levels as the dose of cabergoline was gradually optimized up

Table I: Serial serum hormones and thyroid autoantibody measurements on follow-up. (ND - Not done)

	Normal	Baseline	6 weeks	5 months	7 months	8 months
Prolactin (mU/L)	70 - 550	14660	4653	4800	1892	343
Random GH (mIU/L)	0.13 - 5.0	11.2	3.6	0.58	0.3	ND
IGF-1 (IU/ml)	0.34 - 1.42	3.20	2.40	1.10	0.90	
Free T4 (pmol/L)	9.0 - 26.0	58.8	21.1	18.9	12.3	12.5
Total T3 (nmol/L)	1.1 - 2.7	5.3	1.6	1.6	0.8	1.4
TSH (mU/L)	0.1 - 4.0	<0.04	<0.04	0.38	0.12	0.29
Testosterone (nmol/L)	7 - 28	1.7	1.1	ND	4.6	ND
FSH (mU/L)	1.0 - 10.5	1.1	2.2	ND	3.7	ND
LH (mU/L)	1.0 - 8.4	0.8	1.2	ND	2.3	ND
TSH R Abs (arb. units)	-15 to +15	19.0	ND	ND	19.0	ND
Tg Abs (IU/ml)	<100	340	ND	ND	35	ND
TPO Abs (IU/ml)	<100	620	ND	ND	110	

CASE REPORT

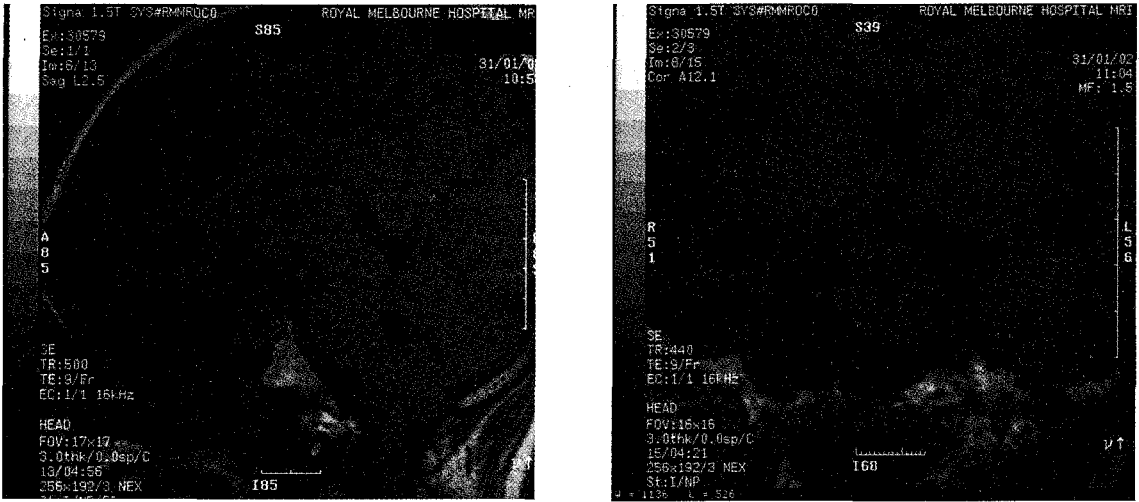


Fig. 1: MRI of pituitary gland in sagittal [(A)] and coronal [(B)] view before initiation of dopamine agonist therapy. The pituitary fossa is enlarged and contains an intrasellar mass, approximately 1.5cm in diameter. There was suprasellar extension with the mass abutting the optic chiasm superiorly. The tumour appeared to partially surround the left intra-cavernous internal carotid artery but no cavernous sinus invasion was seen.

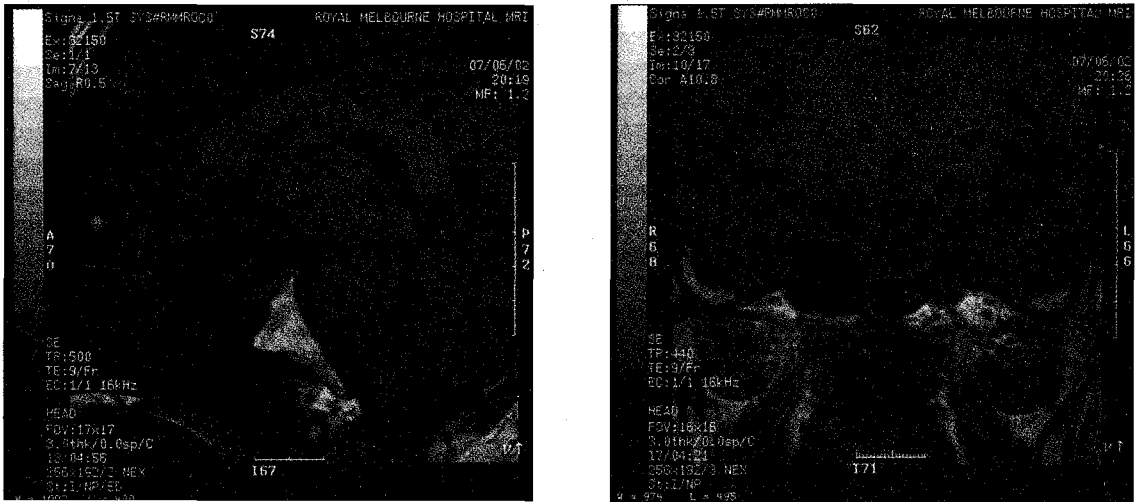


Fig. 2: MRI of pituitary gland after 4 months of dopamine agonist therapy showing significant decrease in size of the pituitary mass with the optic chiasm situated more inferiorly than previously.

to a total dose of 3mg weekly. A repeat MRI scan at 4 months revealed a significant decrease in the size of the pituitary mass with the optic chiasm situated more inferiorly than previously (Figure 2). PRL levels normalised 8 months after initiating therapy and this was accompanied by a corresponding reduction in serum GH and IGF-1 levels. Serum T levels remained low despite normalization of PRL and gonadotrophin levels. He did not receive T replacement therapy during this period, as we were keen to assess the response of the hypogonadism following treatment of hyperprolactinemia. This was explained to the patient and he agreed that testosterone replacement would be considered if hypogonadism remained irreversible following restoration of normoprolactinaemia.

Discussion

This case is notable because of the simultaneous presentation of Graves' disease in a patient with a macroprolactinoma and associated GH excess. We considered the most likely diagnosis was of combined secretion of PRL and GH from the pituitary tumour. However, a differential diagnosis would be a pituitary tumor secreting PRL solely with altered patterns of GH secretion related to the hyperthyroidism. Various abnormalities in GH release have been reported in states of thyroid dysfunction. It is also of interest that hyperprolactinemia may have played a role in promoting autoimmune thyroid disease in our patient and the treatment of hyperprolactinaemia may have played a role in suppressing autoimmune disease activity in Graves' disease. PRL has previously been identified as an immunomodulator in both central and peripheral lymphoid organs and hyperprolactinemia has been implicated in a number of immune-mediated diseases¹.

There are limited descriptions of co-existence of hyperprolactinemia and autoimmune thyroid disease in the literature. It has been suggested that high levels of prolactin in serum can stimulate autoantibody production in individuals without clinically apparent autoimmune diseases. Ferrari *et al*² investigated the occurrence of thyroid autoantibodies in 82 women and 10 men with hyperprolactinemia of various aetiologies (10% macroprolactinoma, 24% microprolactinoma, 4% acromegaly, 50% idiopathic hyperprolactinemia) compared with 185 controls. Two patients had thyrotoxicosis, one due to Graves' disease and the other due to autonomous thyroid adenoma. High titres

of antithyroglobulin antibodies ($\geq 1/1250$) and antimicrosomal antibodies ($\geq 1/1600$) were detected in 19.5% and 12.2% of study subjects, respectively. Among the control group 3.3% of females and 2.5% of males had low titer antithyroid antibodies and none had high titre antibodies. One series from Japan reported a prevalence of 19% of antithyroglobulin antibodies in hyperprolactinemic men compared with 2% in normal men. It has also been observed that among prolactinoma patients, those with positive antibody titers had higher prolactin levels than those with negative antibody titers. We observed a normalization of the thyroglobulin and thyroid peroxidase antibodies with correction of hyperprolactinemia and antithyroid therapy, suggesting a reduction in autoimmune disease activity. However, there has been no change in the TSH receptor antibody level after 7 months of antithyroid treatment. A recent published report described a significant reduction in T4 and T3 levels in euthyroid patients following cabergoline therapy for prolactinoma, which had necessitated thyroxine replacement in some patients³.

Morphologic changes in anterior pituitary cells of patients with hyperthyroidism have previously been reported. Scheithauer *et al.* performed a histopathological study on autopsy-derived pituitary glands of 33 patients who died with hyperthyroidism (18 patients with Graves' disease and 15 with toxic multinodular goitre). Pituitary adenomas were found in 18% (6 of 33), half of these demonstrated immunoreactivity for PRL and 2 for GH. No thyrotrophin containing tumors were found and no evidence of hypophysitis or fibrosis was seen in any of the cases.

Thyroid hormones influence synthesis and secretion of GH by acting directly on anterior pituitary somatotrophs as well as at the hypothalamic level, to modulate release of GHRH and somatostatin. Iranmanesh *et al.*⁴ reported an almost 4-fold increase in the 24h GH secretion rate in hyperthyroid patients possibly related to an increase in endogenous GHRH secretion. It has also been reported that thyroid hormones exert a suppressive effect on GH secretion by normal somatotrophs but spontaneous GH secretion from neoplastic somatotrophs are stimulated in the hyperthyroid state. The possible stimulatory effect of thyroid hormone on human pituitary GH gene transcription has also been investigated. The mechanisms underlying the altered GH secretion seen in hyperthyroidism are not fully understood. In this

CASE REPORT

patient, the achievement of a euthyroid state after administration of antithyroid drug may also have contributed to the improvement in GH levels. Shimatsu *et al.*⁵ described reduction in GH levels when their acromegalic patient became euthyroid after administration of antithyroid drugs and radioactive iodine.

Thyroid hormones are also important regulators of PRL secretion. In hyperthyroidism, PRL response to TRH stimulation is reduced and this may be explained by direct pituitary inhibition of PRL synthesis and secretion by thyroid hormones and possibly through changes in the number of TRH receptors on the lactotrophs. Impaired PRL secretion in hyperthyroid patients could also be related to an alteration at the hypothalamic level. The pathophysiological significance of pituitary PRL depletion in hyperthyroid patients is not well established and the effects of hyperthyroidism on prolactin secretion in patients with prolactinomas have not been studied.

Hyperthyroidism is also associated with major alterations in T metabolism. The serum sex hormone-binding globulin (SHBG) concentrations are increased with elevated levels of total T but free T levels remain normal or are depressed. Thus in our patient the low serum T level in the presence of thyrotoxicosis at presentation may actually be masking an even lower actual T level. Following the initial six weeks of antithyroid treatment, we observed a surprising reduction in serum T levels despite a rapid reduction in serum PRL levels. This may relate to reduced serum

SHBG levels with correction of the hyperthyroid state. We did not measure SHBG levels in our patient. This was followed by a slow increase in serum T levels reflecting the delayed recovery of the hypothalamic-pituitary-testicular axis. It has been observed that dopamine agonist therapy may not restore gonadal function in all men with prolactinomas. Hypogonadism persists in 50% of men with treated macroprolactinomas; in these patients it is assumed that destruction of gonadotrophs has occurred and exogenous androgen replacement is required. Although testosterone replacement will normalise serum testosterone levels, sexual dysfunction may persist in some patients.

In summary, we have described the very rare coexistence of Graves' disease with a pituitary macroadenoma co-secreting prolactin and GH and the successful response to medical therapy with antithyroid and dopamine agonist treatment. While the association of nodular goitre, hyperthyroidism and GH excess is common, the coexistence of Graves' disease and prolactinoma has only been described several times previously. Although we cannot definitively establish cause and effect, we hypothesise that hyperprolactinemia may have played a part in triggering and exacerbating the autoimmune thyroid disease in this case. Further studies in patients with Graves' disease and other autoimmune thyroid disease may be helpful to study the interactions between neuroendocrine and immune systems. Our case also reflects on the close and complex interactions between thyroid hormones, PRL, GH and testosterone.

References

1. Reber PM. Prolactin and immunomodulation. *Am J Med.* 1993; 95: 637-43.
2. Ferrari C, Boghen M, Paracchi A, Rampini P, Raiteri F, Benco R, et al. Thyroid autoimmunity in hyperprolactinemic disorders. *Acta Endocrinologica* 1983; 104: 35-41.
3. Keogh MA, Wittert GA. Effect of cabergoline on thyroid function in hyperprolactinemia. *Clin Endocrinol* 2002; 57: 699.
4. Iranmanesh A, Lizarralde G, Johnson ML, Veldhuis JD. Nature of altered GH secretion in hyperthyroidism. *J Clin Endocrinol Metab.* 1991; 72: 108-15.
5. Shimatsu A, Murabe H, Sasaki S, Hattori N, Tanoh T, Imura H. Secretory dynamics of growth hormone in an acromegalic patient associated with Grave's disease. *J Clin Endocrinol Metab.* 1990; 71: 1059-63.