

Abdominal Aorta and Inferior Vena Cava Thromboses in Advanced Stage of Malignant Fibrous Histiocytoma

W I Faisham, MMed (Ortho)*, W Zulmi, MS (Ortho)*, A M Ezane, MMed (Rad)**, B M Biswal, MD ***

*Department of Orthopaedic, **Department of Radiology, ***Department of Oncology and Radiotherapy, School of Medical Sciences, Universiti Sains Malaysia, 16150 Kubang Kerian, Kelantan

Summary

Asymptomatic simultaneous thrombosis of abdominal aorta and inferior vena cava is a rare complication in advanced malignancy. We described an incidental finding of this clinical entity in our patient who presented with advanced stage of malignant fibrous histiocytoma of soft tissue and pathological fracture. The radiological evaluation with spiral computed tomography scan of abdominal aorta and inferior vena cava are presented and the subsequent management highlighted.

Key Words: Asymptomatic, Abdominal aorta, Inferior vena cava, Thrombosis

Case report

A forty-seven-year old lady presented to our center with pathological fracture of the mid-shaft of the right femur following trivial injury in the bathroom. Prior to the admission she had experienced six months of right gluteal swelling which was painless and had not interfered with her daily activities. She had noted significant loss of appetite and weight for the past four months. Examination revealed a fracture of the femur with a vague mass over the thigh. The right gluteal swelling was firm but non-tender and diffusely infiltrating into the substance of gluteus maximus.

Radiograph of the right thigh confirmed a mid-shaft femoral fracture with diffuse moth-eaten osteolytic lesion involving both fracture fragments and having a wide zone transition. Computed tomography scan of thorax and abdomen showed multiple liver metastases with hepatic portal nodes involvement. Complete obliteration of the descending aorta seen at the level of

second lumbar vertebra with complete obstruction below the origin of renal arteries and extending just proximally to the level of bifurcation. The common, superficial and deep femoral arteries were however patent and received supply from collateral vessels. Inferior vena cava was also noted to be thrombosed at the level of lumbar 3 and lumbar 4 vertebrae and extending to the common iliac vein. (Fig.1 and 2) There was no evidence of metastases to the lung.

The patient underwent an intramedullary fixation with Kuntcher nail augmented with polymethylmethacrylate bone cement. This was aimed to stabilise the fracture, minimise pain and allow early ambulation. Histopathological study of tissue from the resected segment showed multiple fragments of tumour tissue composed of malignant spindle shaped cells consistent with a diagnosis of malignant fibrous histiocytoma.

The postoperative period was uneventful. She was allowed to ambulate with walking aid a week after

This article was accepted: 19 April 2005

Corresponding Author: W I Faisham, Department of Orthopaedic, School of Medical Sciences, Universiti Sains Malaysia, 16150 Kubang Kerian, Kelantan

CASE REPORT

surgery. Despite the above findings, there were no symptoms of vascular insufficiency to the lower limb or associated limb oedema. External beam radiation of 20 cGy was given in five divided fractions to the right thigh and the gluteal region after 2 weeks after postoperative periods, followed by six courses of chemotherapy. She was started on a loading dose of heparin followed by oral anticoagulants even though the thrombosis was asymptomatic. She was able to proceed with her normal daily activity and ambulating pain free with no symptoms of peripheral vascular insufficiency or pulmonary embolism. Twelve month later she died of disseminated cancer.

Discussion

Trousseau is considered the first to have described a relationship between thromboembolism and internal malignancy. The condition is a complication of deep-seated cancer especially primary cancers from the pancreas, lung, stomach and female genital tract¹. It is a rare presentation of soft tissue sarcoma such as malignant fibrous histiocytoma as described here. Venous thromboembolic events are common in patients with cancer, accounting for significant morbidity and mortality. When venous thromboembolism presents

concurrently with a diagnosis of cancer, this suggests a more advanced disease associated with occult distant metastases with consequent poor prognosis and survival². The goal in the management is to prevent progression and recurrence of thrombosis while minimising complications of treatment.

The biologic plausibility of a causal relationship between cancer and vasculopathy emerges from the current understanding of the pathophysiology of paraneoplastic disorders. Certain paraneoplastic mediators are simply normal cell products secreted in excess because of the increased mass of tumoral tissue. These circulating mediators may damage vascular endothelial cells and activate the coagulation cascade. The clinical course of paraneoplastic vascular disorders usually parallels that of the tumor; control of the neoplasia usually results in regression of the paraneoplastic vascular disorder^{2,3,4}.

The management of major veins and arterial thromboses in patients with cancer can be a dilemma. Complete obstruction of aorta and inferior vena cava without symptoms raised a question whether "one should do something active surgically". Surgical resection and bypass procedure had been advocated,

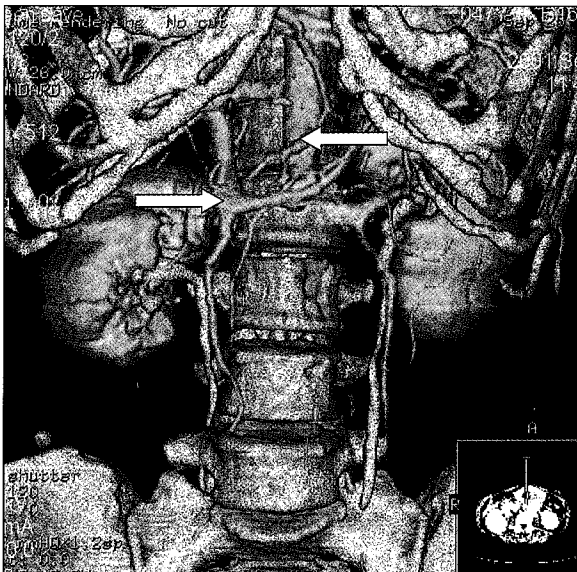


Fig. 1: Contrast enhanced spiral computed tomography scan showed abdominal aorta inferior vena cava thrombosis

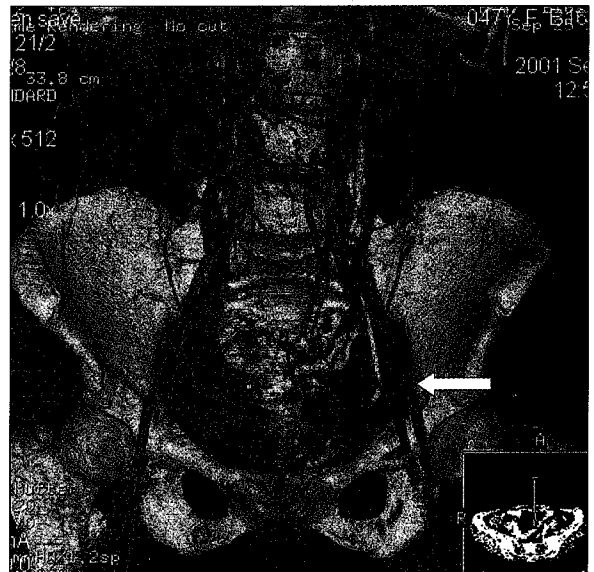


Fig. 2: Common, superficial and deep femoral arteries received supply from collateral vessels

however the morbidity and mortality in this group of patient is significantly high³. This case highlights the systemic treatment of cancer and the conventional management of thrombosis with anticoagulation. Major vascular surgical intervention was avoided in this patient in view of poor prognosis.

Conclusion

The thrombosis of abdominal aorta and inferior vena cava are rare complications of malignant fibrous histiocytoma. Conventional treatment with anticoagulants for asymptomatic obstruction of aorta and inferior vena cava in advanced disease is still considered adequate.

References

1. Otten HM, Prins MH. Venous thromboembolism and occult malignancy. *Thromb. Res.* 2001; 102(6): 187-94.
2. Sorensen HT, Mellekjaer L, Olsen JH, Baron JA. Prognosis of cancers associated with venous thromboembolism. *N Engl J Med* 2000; 343: 1846-50.
3. Hillen HF. Thrombosis in cancer patients. *Ann Oncol.* 2000; 11(suppl 3): 273-76.
4. Naschitz JE, Yeshurun D, Lev LM. Thromboembolism in cancer. Changing trends. *Cancer* 1993; 71: 1384-390.
5. Lifante JC, Glehen O, Peyrat P, Paparel P. Segmental resection of tumoral invasion of inferior vena cava without reconstruction. *Ann. Chir.* 2001; 126(1): 46-50.