

Bilateral Lacrimal Sac Mucocele With Punctal and Canalicular Atresia

C A Ong, MBBS*, N Prepageran, FRCS (ORL)*, G Sharad, MS (ORL)**, D Luna, FRCS (Ophth)**

*ENT Department, University Malaya Medical Center, 50603 Kuala Lumpur, **Department of ENT, Department of Ophthalmology, Queen Elizabeth Hospital, Kota Kinabalu, Sabah

Summary

Congenital absence of lacrimal puncta may be an isolated finding or associated with other developmental abnormality. Nasolacrimal ducts can be absent thus predisposing to the formation of a congenital lacrimal mucocele. Punctal and canalicular agenesis is very rare. Four percent of new patients attending the lacrimal clinic at Moorfields Eye Hospital, London, UK, from 1981 to 1990 inclusive were diagnosed to have this condition. We describe a case of bilateral congenital absence of lacrimal puncta with lacrimal mucocele. Combined surgery was carried out by Ophthalmologist and Otolaryngologist with successful results.

Key Words: Congenital, Lacrimal sac mucocele, Punctal atresia

Case Report

A 15 year-old school boy presented to the Ophthalmology Clinic with bilateral swelling over the medial canthus of 6 years duration. The swelling fluctuates in size spontaneously with no predisposing factors and he has been having excessive tearing of both eyes since childhood. Otherwise, he was asymptomatic.

On examination, bilateral swelling were noted on the medial canthus. The right swelling measured 4 x 4cm while the left measured 3 x 3cm (Figure 1). Both were non tender and cystic in nature. There was absence of both the upper and lower puncta, bilaterally. The rest of the eye and nasal examination was normal. A clinical diagnosis of lacrimal sac mucocele with bilateral congenital absence of lower and upper puncta was made.

CT scan revealed bilaterally enlarged lacrimal sacs, consistent with lacrimal sac mucocele with nasolacrimal duct atresia (Figure 2). A final diagnosis of bilateral

lacrimal mucocele with bilateral punctal and nasolacrimal duct atresia was concluded. A combined surgery was carried out by the Ophthalmologist and ENT surgeon under general anaesthesia. Bilateral endoscopic dacryocystorhinostomy was performed after creating new puncta surgically.

The lacrimal sac was opened into the nasal cavity endoscopically under the guidance of fiberoptic light passed through the created punctum. Thick mucoid secretion was cleared from the lacrimal sac and silicone tubes (Crawfords tubes) were inserted via the surgically created punctum into the lacrimal sac and into the nasal cavity. This was held in place by knotting the silicone tubes in the nasal cavity. The postoperative recovery was uneventful and he was discharged 2 days later. On follow up, the patient was well and the tubes were removed 6 weeks later. The created tracts were patent as the patient could feel eyedrops trickle into his nose. He is now symptom free with no evidence of recurrence for more than 2 1/2 years till present. (Figure 3).

This article was accepted: 29 June 2005

Corresponding Author: C A Ong, ENT Department, University Malaya Medical Centre, 50603 Kuala Lumpur

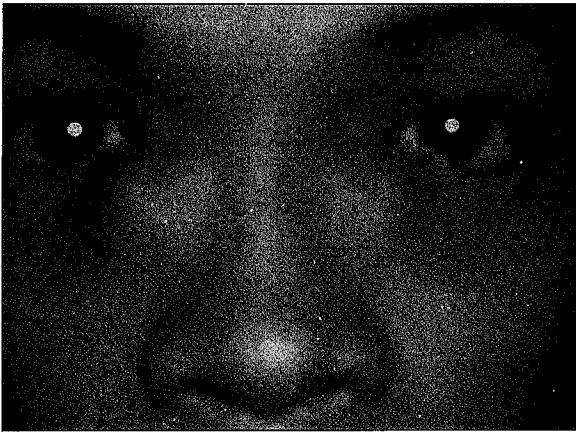


Fig. 1: Preoperative picture of the patient. Bilateral swelling over the medial canthus

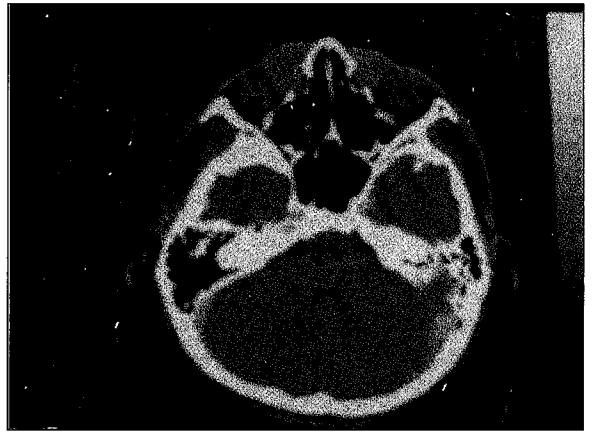


Fig. 2: CT scan revealing bilateral lacrimal mucocele




Fig. 3

Discussion

Abnormalities of the lacrimal system is uncommon and can be difficult to treat. In comparison, nasolacrimal duct obstruction is a very common anomaly which can be readily treated¹. Punctal agenesis is usually associated with the absence of underlying canalicular tissue. This predisposes to the formation of lacrimal sac mucocele. Lyons CJ et al² reported 86% absence of identifiable canalicular tissue in patients with bilateral punctal atresia. When normal canalicular tissue lies within the eyelid of a patient with punctal atresia, it may be successfully exteriorized to the conjunctival surface, thus relieving the symptom of epiphora². Absence of nasolacrimal duct and canalicular tissue

however, is difficult to treat. These would need insertion of Jones silicone tube or in cases with more clinically obvious abnormalities, additional dacryocystorhinostomy or conjunctivo- dacryocystorhinostomy will be required³.

Dacryocystorhinostomy was first described by Toti in 1904. Since then, the majority of DCR has been via an external approach. Intranasal approach to the lacrimal apparatus, avoiding an external scar, was limited by poor visibility within the narrow confines of the superior meatus. Surgical access throughout the nasal cavity has been enhanced by endoscopic nasal surgery. Small diameter endoscopes with angled vision provide excellent intranasal visualization, enabling the surgeon to identify and open the lacrimal sac with relative ease. It provides direct vision of the lacrimal sac, making the procedure safe even in the presence of fibrosis from previous surgery. Intranasal pathology that contributes to DCR failure, such as postoperative adhesions, enlarged middle turbinate and deviated nasal septum can be readily identified and corrected via endoscope⁴.

The use of silicone tube which is left in situ for a few weeks is to facilitate the formation of a tract from the new surgically created punctum into the lacrimal sac and draining into the nasal cavity. This forms a surgically constructed new punctal, canalicular and nasolacrimal system which reduces epiphora and prevents the formation of lacrimal mucocele. Fibrosis and closure of the surgically created tract might cause recurrence and would require revision surgery.

CASE REPORT

REFERENCES

1. Moore BD. Lacrimal system abnormalities. *Optom Vis Sci* 1994; 71(3): 182-3.
2. Lyons CJ, Rosser PM, Welham RA. The management of punctal agenesis. *Ophthalmology* 1993; 100(12): 1851-5.
3. Boerner M, Sieff SR, Arroyo J. Congenital absence of the lacrimal puncta. *Ophthalmic Surg* 1995; 26(1): 53-6.
4. Krishnan G, Prepageran N, Kumar M. Endonasal Endoscopic Dacryocystorhinostomy. *Medical Journal of Malaysia* Dec 2002; 57(4): 493-5.