

Massive Epistaxis Secondary to Pseudoaneurysm of Internal Carotid Artery

A Asma, MS (ORL-HNS), S H A Primuharsa Putra, MS (ORL-HNS), L Saim, FRCS

Department of Otorhinolaryngology, Medical Faculty, University Kebangsaan Malaysia, Jalan Yaakub Latif, 56000 Cheras, Kuala Lumpur

Summary

Post-traumatic pseudoaneurysms of internal carotid arteries are uncommon. The patients may present with massive epistaxis due to rupture of the aneurysm into the sphenoid sinus. Early diagnosis and treatment is mandatory as the likelihood of exsanguinations increases with each subsequent episode of epistaxis. The clinical features of unilateral blindness and massive epistaxis after head injury should indicate the diagnosis. The high mortality of this entity underlines the importance of early angiography in these patients to confirm this diagnosis. We present 3 cases of post-traumatic aneurysm of the ICA.

Key Words: Pseudoaneurysm, Internal carotid artery, Massive epistaxis

Introduction

A severe head injury associated with basal skull fracture may rarely cause a pseudoaneurysm of internal carotid artery. These patients are usually admitted to a regional neurosurgery unit and treated either medically or surgically depending on the severity of head injury. After a short period, the patient is discharged and later most of them are re-admitted again with massive epistaxis. We present 3 cases of pseudoaneurysm of internal carotid artery and highlight their management.

Case Report

Case 1

A 25-year-old Malay man was involved in a motor vehicle accident. He sustained severe head injuries and left blindness. He made an uneventful recovery and was discharged well. Two months later, he began to have frequent headaches and repeated episodes of epistaxis. During the last episode he developed profuse epistaxis with hypotension that required resuscitation.

His general condition was satisfactory except for mild pallor. There was no evidence of bleeding on nasal endoscopy. The left eye showed no reaction to light. There was no bruit or ecchymosis and the range of movement was normal. Remaining ear, nose and throat examination was normal. After an uneventful period of observation in the ward the patients as discharged.

A week later, he had a massive epistaxis at home. On arrival to our unit, an emergency internal carotid angiogram was performed. Leakage of contrast from the cavernous portion of the left ICA, forming a pseudoaneurysm in the sphenoid sinus, was demonstrated. No other vascular abnormality was noted. There was no evidence of early venous filling to suggest a carotid cavernous fistula. Good collateral circulation from right to left was noted on simultaneous compression of the left carotid artery and injection on the right side.

In view of the above findings, ligation of the left internal carotid artery in the neck was performed.

This article was accepted: 2 September 2005

Corresponding Author: Asma Abdullah, Department of Otorhinolaryngology, Medical Faculty, University Kebangsaan Malaysia, Jalan Yaakub Latif, 56000 Cheras, Kuala Lumpur

Postoperatively no hemiparesis was noted. The bleeding stopped and a repeat computerized tomography (CT) scan with contrast injection did not show any refilling of contrast in the aneurysm.

However, one month later, he had three further bouts of severe bleeding at home. He was resuscitated and a repeat CT scan noted a false aneurysm at the previous pseudoaneurysm site. An angiography of the left ICA was performed and confirmed the finding. There was no cross filling of the aneurysm from the contralateral right internal carotid artery. The patient underwent clipping of the intracranial portion of the ICA. Through a left pterional craniotomy, the left ICA was clipped below the ophthalmic artery as close to its intradural origin as possible. He was nursed in intensive care unit for 48 hours post-operatively. He made an uneventful recovery from the operation and no focal neurological deficit was noted. Since September 1997, he has remained well with no further epistaxis.

Case 2

A 22-year-old Malay man presented with progressive loss of left vision and frontal headache for three months. Four months prior to admission, he was involved in a motor vehicle accident and sustained severe head injuries. There was no history of recurrent epistaxis.

On examination, he was blind on the right while the visual acuity in the left eye was 1/60. There was no ecchymosis and the range of movement was full. No bruit was detected in the orbital region. Fundoscopy revealed bilateral optic atrophy. The rest of the head and neck examination was normal. While in the ward he had two episodes of sudden spontaneous massive epistaxis requiring bilateral anterior nasal pack. A computed tomography (CT scan) with contrast enhancement revealed a dense area in the region of the sphenoid sinus. Angiography with cross flow study showed a large right ICA aneurysm with extension into the sphenoid sinus.

There was good collateral circulation from left ICA to right side of brain. The right ICA was ligated in the neck. No intracranial clipping of the right ICA was attempted. The postoperative recovery was uneventful with no evidence of neurological deficit. He was asymptomatic on his last follow up in March this year.

Case 3

A 31-year-old Chinese man, had facial trauma following an assault in December 2000. He sustained subdural

haematoma of the right frontal area with an overlying fracture of frontal bone and sinus. He also had multiple fractures over the right maxillary sinus, sphenoid sinus, right zygomatic arch and right orbital wall. There was no visual impairment. Evacuation of subdural haematoma was performed, and the patient recovered well from the injuries.

Three months later he presented with history of right recurrent massive epistaxis. There was no proptosis or conjunctiva congestion. The nasal endoscopy was normal. There was no bruit over the frontal or nasal region. A provisional diagnosis of post-traumatic pseudoaneurysm of internal carotid artery was made. An urgent four vessels angiogram and right external angiogram was performed.

The carotid angiography showed a pseudoaneurysm arising from cavernous part of right internal carotid artery just proximal to the right ophthalmic artery. (Figure 1) The left carotid circulation was normal. There was good collateral circulation from left to the right side of brain. The right internal carotid was ligated in the neck. The postoperative recovery was uneventful. There was no evidence of recurrent epistaxis since December 2000.

Discussion

Although massive epistaxis from pseudoaneurysm of the ICA is a rare entity, it should be considered in the search for the cause of massive epistaxis, particularly when it is associated with severe head injury. An aneurysms or pseudoaneurysm may cause symptoms by encroaching on surrounding structures as it expands (local mass effect). Thus massive epistaxis associated with blindness post trauma as seen in case 1 and 2 should arouse the suspicion of ICA pseudoaneurysm. It may present acutely with rupture and causing massive epistaxis, distal embolization, thrombosis and arteriovenous fistula i.e. carotico-cavernous fistula.

Wang et al¹ reported aneurysms involving the intracavernous portion of the ICA with erosion and rupture into the sphenoid sinus presenting with delayed massive epistaxis as seen in case 3. The III, IV and VI cranial nerves, as well as the first and second division of the V cranial nerve, can also be involved. Traumatic lesion of the intracavernous portion of ICA can also cause a carotico-cavernous fistula. However, the cardinal symptoms of such a major arterio-venous fistula are often dramatic and typical that the diagnosis

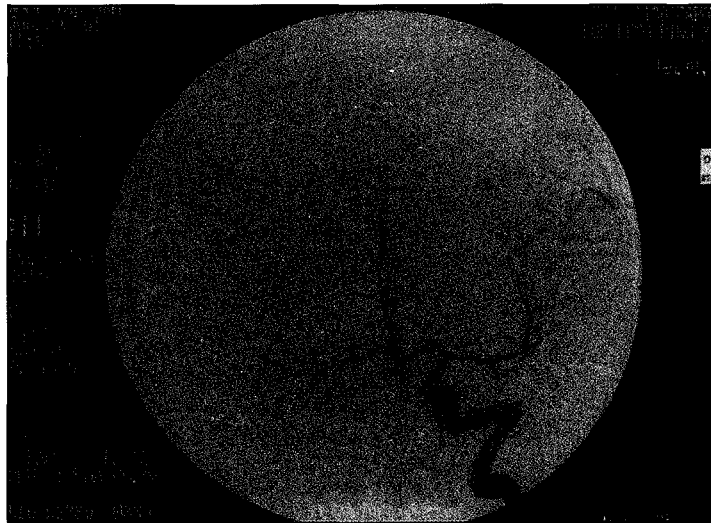


Fig. 1: Carotid angiogram showed a pseudoaneurysm arising from cavernous part of right internal carotid artery. It was located just proximal to the right ophthalmic artery.

becomes evident early and can be differentiated easily from an aneurysm of the ICA.

The cause of an intracavernous traumatic aneurysm in the third case, rather than a fistula, is probably explained by the microanatomy of the cavernous sinus, which is composed of formed venous vessels¹. If the walls of these veins in the sinus are not disrupted but are instead compressed by the blood extravasated from a damaged adjacent carotid artery, a pseudoaneurysm rather than a fistula may develop¹.

Aneurysm of the ICA should be suspected in patients presenting with massive epistaxis after severe head trauma. In a majority of cases epistaxis occurred 1-3 months post injury². In this series of three cases, they had epistaxis within this period, although a latent period of up to one year has been reported¹. Visual loss, either permanent or temporary as evident in our two cases may be caused by permanent damage to the optic nerve or the ophthalmic artery³.

The main diagnostic investigations performed were computed tomography (CT) scan and angiographies. CT scan may demonstrate the site of bony fractures and involvement of the sphenoid sinus. Unilateral opacification of the sphenoid sinus, occasionally with

an enhancing rounded mass, may be evident. Angiogram is the procedure of choice for definitive diagnosis of the intracavernous carotid aneurysm, which is usually found occupying the sphenoid sinus¹. In 6% of cases the initial angiogram may be normal and the aneurysm is only demonstrated later at a study performed during the time of epistaxis³.


Early treatment of an ICA aneurysm is essential to prevent death. Emergency control of massive epistaxis can be achieved by immediate placement of anterior and posterior nasal packing. Placement of bilateral epistaxis balloon catheters or a Foley's catheter has also been suggested.

Many different techniques have been mentioned in the management of aneurysm or pseudoaneurysm namely ligation, embolization, resection with allografts or homograft and endovascular technique with stent graft. There are many embolic materials for embolizations such as polyvinyl alcohol (PVA), gel foam powder, silicon balloon, latex balloon, micro coils and cyanoacrylates. Each option has its advantages and disadvantages.

Ligation of the ICA is the treatment of choice as demonstrated in our cases. Ligations of the cervical

ICA will lower the perfusion pressure in the pseudoaneurysm thus preventing further rupture of the pseudoaneurysm. However, this proved to be insufficient in case 1 where a trapping procedure eventually had to be performed. Ligation of the ICA is relatively easy procedure and does not require specialised skill or instrumentation but has a risk of stroke and blindness.

We believe that early diagnosis and treatment is mandatory in managing pseudoaneurysm. Therefore, patients with epistaxis and a history of prior severe head injury should be examined and investigated for possible ICA pseudoaneurysm. Ligation of the ICA is the treatment of choice as demonstrated. Ligation of the cervical ICA will lower the perfusion pressure in the pseudoaneurysm thus preventing further rupture of the pseudoaneurysm.

-
- 
1. Wang AN, Winfei JA, Guger G. Traumatic internal carotid artery aneurysm with rupture into the sphenoid sinus. *Surg. Neurol.* 1986; 25: 77-1.
 2. Hern JD, Colley SC, Hollis LJ et al. Delayed massive epistaxis, due to traumatic intracavernous carotid artery aneurysm. *J Laryngol Otol.* 1998; 112: 396-1.
 3. Lee JP, Wang ADJ. Epistaxis due to traumatic intracavernous aneurysm. *J. Trauma.* 1990; 30: 619-2.