

# Percutaneous Transpedicular Biopsy of the Spine

Y S Chooi, MBBS, MS.Orth, Ozlan I M Kamil, MBBS, MS.Orth, M Fazir, MBBS, MS.Orth, Sidik Che Kob, MBBS

Department Orthopaedics and Traumatology, Hospital Kuala Lumpur, Jalan Pahang, 50586 Kuala Lumpur

## SUMMARY

An open biopsy has minimal sampling error, but is a major procedure, with its inherent complications and morbidity. The complications of paraspinal needle biopsy of vertebral lesions are well known. Needle biopsies have a high incidence of false negatives, especially for tumors. Percutaneous transpedicular biopsy is efficacious, safe, and cost effective, and mostly performed under local anesthesia. Fluoroscopic monitoring enables real time positioning of the needle. Serious needle complications from percutaneous needle biopsy are uncommon. More than 50% of vertebral body tissue, including the disc is accessible via a unilateral transpedicular approach and amenable for biopsy.

## KEY WORDS:

*Percutaneous transpedicular, Spinal biopsy, Fluoroscopic*

## INTRODUCTION

It is generally accepted that open biopsy of spinal lesions produces the greatest amount of tissue, thus improving the chance of a positive yield. In relative terms, an open biopsy is a major procedure which naturally has its own potential complications and morbidity. In the authors' centre, an open biopsy is usually performed after a negative result following the radiologist's CT-guided needle biopsy; or in selected presumed tumors mainly affecting the posterior elements of the spine.

The potential complications of a paraspinal needle biopsy technique have been well documented. The commoner ones being nerve root injury, pneumothorax, and troublesome hematoma formation. This technique is also associated with a high incidence of false negative results, especially in cases with thick sclerotic bone not uncommon in osteoblastic tumors<sup>1</sup>. The technique of a percutaneous transpedicular biopsy of spinal lesions has been shown to be a useful alternative to paraspinal biopsy for vertebral body lesions in the thoracic and lumbosacral spine<sup>2</sup>. The versatility of this efficacious, safe and cost effective technique is further enhanced by the possibility of using local anaesthesia, with fluoroscopic or CT guidance<sup>3</sup>. The authors now report their early experience with the technique of transpedicular biopsy of vertebral body lesions.

## MATERIALS AND METHODS

Since January 2002, percutaneous transpedicular biopsy of lower thoracic and lumbar vertebral lesions have been performed in 30 patients. There were 22 male patients and 8 female patients. The mean age was 52 years old (range 16 – 75 years old). There were one 8 thoracic, 21 lumbar and one sacral biopsy specimens. All were done under fluoroscopic

guidance. Twenty-three specimens were obtained with the patient under general anesthesia, while seven specimens were obtained with the patient under local anesthesia.

## The Technique

The pedicle selected for the vertebral biopsy depends on the location of the lesion within the vertebrae. A review of the patient's X-rays, CT or MRI scans is mandatory. A C-arm image intensifier is used for continuous monitoring during the procedure. The patient is placed in the prone position on the fluoroscopy table. The chosen vertebral level is first visualised in the AP view. In the AP view, the C-arm is manipulated along the inclination of the pedicle until an end-on or bull's eyes view of the pedicle is obtained.

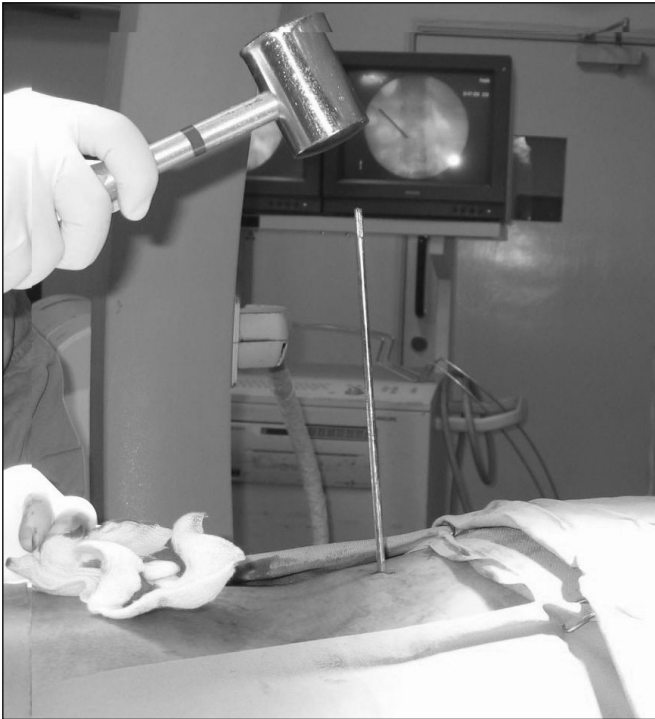
We use the instruments in the Craig biopsy set for the procedures. The biopsy instruments are adjusted until they appear end-on in the AP view on fluoroscopy. For cases done under local anesthesia, the needle track is anesthetized using 1% lignocaine, and the periosteum surrounding the pedicle and the area at the junction of superior facet. A Steinmann guiding pin (2-mm diameter) is positioned in an end-on view of the pedicle. A stab incision is made. The guide pin is then tapped gently with a mallet through the pedicle into the intended area of the vertebral body (Fig 1). The track of the guide pin is kept within the margins (medial, lateral, superior, and inferior) of the pedicle. The lateral view on fluoroscopy ensures the correct anterior trajectory. A cannulated sleeve is inserted over the guide pin, with its tip lying just beyond the anterior edge of the pedicle. The guide pin is then removed. A toothed bone-cutting Craig biopsy instrument (3.2mm) is advanced within the sleeve and just beyond the tip of the sleeve into the vertebral body, to obtain specimens (Fig 2). If more tissue is required, the guide pin is reinserted and tilted in various directions to improve tissue sampling. A specialized instrument can also be used to obtain soft tissue samples. At the end of the procedure, the option of obtaining aspirates for cytology is also possible. The integrity of the pedicle margins must be preserved at all times, especially the medial and inferior borders. This is to prevent the spread of hematoma, infection or tumor into the spinal canal. No drain is needed.

## RESULTS

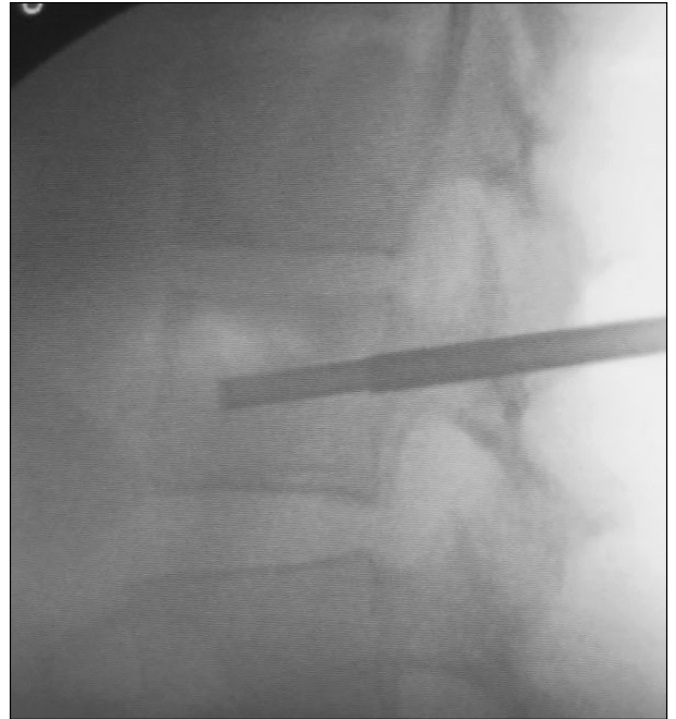
The biopsy specimens are sent for histopathological examination (HPE), Gram staining and microscopic examination (FEME), e.g. acid fast bacilli; cultures and sensitivities (C&S), and Polymerase Chain Reaction for Mycobacterium DNA. Correlations are also made with regards to the laboratory investigations of serum Erythrocyte

*This article was accepted: 10 December 2006*

*Corresponding Author: Chooi Yue Seng, Department Orthopaedics and Traumatology, Hospital Kuala Lumpur, Jalan Pahang, 50586 Kuala Lumpur*



**Fig. 1:** Guide Pin Tapped Gently Into Vertebral Body Via Pedicle With Image Intensifier Control



**Fig. 2:** Tip of Craig Biopsy Instrument Inserted Just Beyond Cannula Sleeve to Obtain Specimen

Sedimentation Rate (ESR), C-reactive Protein (CRP), and serum tumor markers, ie. carcino-embryonic antigen (CEA), alpha feto-protein (AFP), prostate specific antigen (PSA), Carcinoma Antigen (CA) -125 and CA-19.

For ease of discussion, the results are divided into three main areas, ie. spinal tuberculosis, neoplastic and pyogenic conditions. Overall, there were a total of 30 patients, 22 males and 8 females. The mean age was 52 (range 16-75) years old. Twenty-three patients had general anesthesia, while seven patients had local anesthesia. The mean duration of the procedure was 41 (range 15-80) minutes.

There were no significant complications noted.

#### **Tuberculosis of the Spine**

There were 14 patients with 11 males and 3 females. Eleven patients had general anesthesia while three patients had local anesthesia. The mean age was 48 (range 16-67) years old. The commoner biopsy levels were L3 and L4 (31%). The HPE was reported as 'no granuloma' in 50% of the cases, while 'chronic inflammation' in 14%. The ESR was significantly elevated in 79%, while the CRP was only raised in 50% of the cases. Acid fast bacilli was negative in 100%, while cultures were only 30% positive. Only 75% of the cases had PCR for Mycobacterium DNA done, and of those sent, 90% were positive. Eight patients were documented as being treated empirically.

#### **Neoplastic Conditions**

There were 11 patients, seven males and four females. Eight patients had general anesthesia while three patients had local

anesthesia. The mean age was 57 (range 43-68) years old. The commoner levels were L3 (30%), and L1 (20%). The HPE was positive in 89% of the cases. Serum tumor markers were only positive in 57% of the time. ESR was raised in 50% while CRP was raised in 83% of the cases.

#### **Pyogenic Conditions**

There were five patients, with four males and one female. All received general anesthesia. The mean age was 49 (range 28-75) years old. The biopsy levels were between T11 to S1. Cultures and sensitivities were helpful in 70% of cases. The commoner micro-organisms were *Staphylococcus aureus* (50%), and *Pseudomonas aeruginosa*. The ESR was raised in 60%, while CRP was significant in 67% of cases. Significant risk factors included diabetes (three patients) and intravenous drug abuser (one patient).

#### **DISCUSSION**

The procedure per se is not difficult and not very much unlike performing a bone marrow trephine biopsy aspirate, and principles similar to those used for vertebroplasty procedures of the spine. This is reflected in the increasing familiarity of the procedure and the decrease in the duration taken to perform the biopsy. Local anesthesia with some measure of conscious sedation is advantageous as it provides monitoring of nerve root function during the procedure, and thus helps minimize morbidity. The authors recommend local anesthesia only for fit and young patients with reasonable pain threshold. We have found older patients unsuitable for local anesthesia as they seem to tolerate pain poorly, and most likely to have significant co-morbidities. The CT-guided

needle biopsy is performed by the radiologist. Generally, difficult lesions include those 'shielded' areas, e.g. anterior to the transverse process; or 'dangerous' areas, e.g. close proximity to the great vessels. The nature of the fine needle (small bored) also makes sampling thick sclerotic bone difficult.

The transpedicular passage of the biopsy instruments avoids complications associated with paraspinal needle biopsies. This is especially so in the thoracic spine with the pleural space, aortic arch, descending aorta, major veins, esophagus and posterior mediastinum are all potentially at risk. A large series of CT-guided spinal biopsy reported a diagnostic accuracy of 71%, with the thoracic spine having the lowest yield<sup>4</sup>. It has also been shown in cadavers that more than 50% of the vertebral body tissue is accessible through a unilateral transpedicle approach and is amenable for biopsy<sup>2</sup>. The low yield typical of spinal tuberculosis is reflected in the poor results in the HPE, AFB and cultures. Polymerase chain reaction for the detection of Mycobacterium DNA expectedly gave the best results. As for neoplastic lesions, the HPE gives

a good account. The serum tumor markers are only fairly helpful. As for pyogenic lesions of the spine, cultures of biopsy specimens give high positive results. Staphylococcus aureus remains the most common micro-organism.

#### CONCLUSION

For biopsy samples of thoracic and lumbosacral vertebral body lesions, the percutaneous transpedicular approach is a reliable alternative.

#### REFERENCES

1. Kattapuram SV, Khurana JS, Rosenthal DI. Percutaneous needle biopsy of the spine. *Spine* 1992; 17: 561-64.
2. Stringham DR, Hadjipavlou A, Dzioba RB, Lander P. Percutaneous transpedicular biopsy of the spine. *Spine* 1994; 10: 1985-91.
3. Renfrew DL, Whitten CG, Wiese JA, el-Khoury GY, Harris KG. CT-guided percutaneous transpedicular biopsy of the spine. *Radiology* 1991; 180: 574-76.
4. Kornblum MB, Wesolowski DP, Fischgrund JS, Herkkowitz HN. Computed tomography-guided biopsy of the spine: A review of 103 patients. *Spine* 1998; 23: 81-85.