

Oropharyngeal Rhinosporidiosis in a Migrant Worker - A Delayed Presentation

S Shailendra, MS(ORL- HNS), N Prepageran, FRCS

Department of Otorhinolaryngology, University of Malaya, 50603 Kuala Lumpur

SUMMARY

Rhinosporidiosis is a chronic granulomatous disease caused by an aquatic protistan parasite in the class of Mesomycetozoea, that is endemic in India and the subcontinent^{3,4}. This is a case report of a rhinosporidiosis presenting in an individual from Myanmar, whom had been working in Malaysia for the past four years. The disease is characterized by the appearance of polypoidal, friable growths that contain numerous spore filled cysts that stain with PAS staining. This disease is rarely seen in Malaysians due to the extensive urbanization in Kuala Lumpur, however the increasing numbers of migrant workers in Malaysia today necessitates an increasing awareness in clinicians of the possibility of these conditions.

KEY WORDS:

Rhinosporidiosis, Parasite, Migrant worker, Delayed presentation

CASE REPORT

A 38 year old gentleman from Myanmar, who had been working in Malaysia for the past four years presented to our clinic with nasal obstruction, sneezing, foreign body sensation, snoring and dysphagia of six months duration, worsening for the past two months prior to presentation. There were no symptoms of rhinitis or sinusitis. He had been working in Malaysia for the past four years and prior to that was employed in Myanmar as a factory worker. He was employed in the construction sector and did not have any contact with livestock nor did he reside in an area with any

swamps or large bodies of water. Examination revealed multiple large polypoidal, friable growths with a strawberry like appearance involving the floor of the nose, right tonsillar region, soft palate and nasopharynx (Fig. 1).

They were painless and bled slightly on touch. The hypopharyngeal and laryngeal areas looked normal. The growths were biopsied and histopathology revealed that the lesions contained numerous cysts filled with spores and was positive on PAS staining, consistent with Rhinosporidiosis (Fig. 2). The growths were completely excised under general anaesthesia and was uneventful postoperatively. The patient was followed up for three months, till he returned to Myanmar. At the time of discharge there was no recurrence of the disease.

DISCUSSION

Rhinosporidiosis is a chronic granulomatous infection of the mucous membranes that usually manifests as vascular friable polyps that arise from the nasal mucosa or external structures of the eye, initially described by Seeberi in 1900¹. Most cases of rhinosporidiosis occur in persons from or residing in the Indian subcontinent or Sri Lanka.

The etiologic agent, *Rhinosporidium seeberi*, has never been successfully propagated in vitro. Initially thought to be a parasite for more than 50 years, *R seeberi* had been thought to be a water mold.

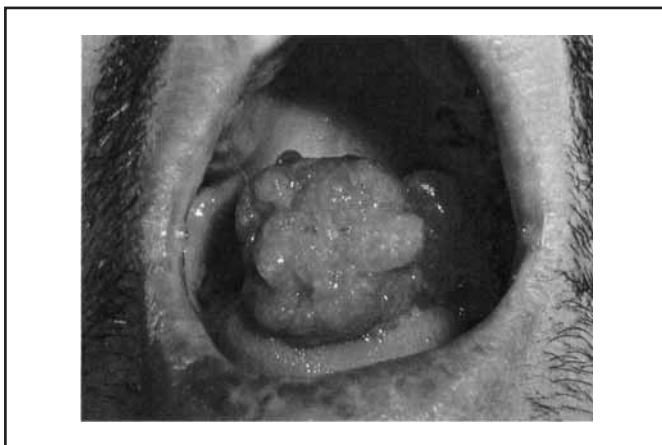

Fig. 1: Appearance of the growth in the patient's Oropharynx

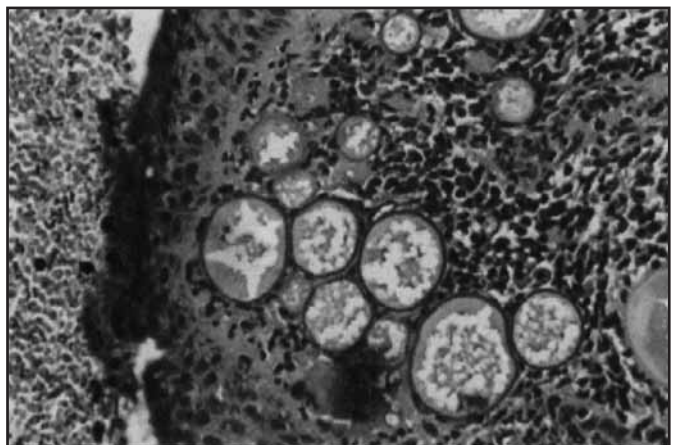


Fig. 2: Histological picture of the specimen showing cysts of *Rhinosporidium Seeberi*

This article was accepted: 18 November 2007

Corresponding Author: Shailendra Sivalingam, Otorhinolaryngology Department, Faculty of Medicine, University of Malaya, 50630 Kuala Lumpur

Molecular biological techniques with 18S rRNA gene analysis have more recently demonstrated that this organism is an aquatic protistan parasite³. It is currently included in a new class, the Mesomycetozoa, along with organisms that cause similar infections in amphibians and fish³. Infection usually results from a local traumatic inoculation with the organism, by bathing in or exposure to contaminated, stagnant water. Disease progresses with the local replication of *R seeberi* and associated hyperplastic growth of host tissue and a localized immune response. The interval between infection and disease presentation is unpredictable and varies widely however as shown by this case. The disease can present clinically even up to four years after initial exposure. Infection of the nose and nasopharynx is observed in 70% of persons with rhinosporidiosis; infection of the palpebral conjunctivae or associated structures (including the lacrimal apparatus) is observed in 15%^{1,3}. Other structures of the mouth and upper airway may be sites of disease.

Nasal disease may present with unilateral nasal obstruction or epistaxis. Other symptoms may include local pruritus, coryza with sneezing, rhinorrhea, and postnasal discharge with cough. Patients often report a sensation that a foreign body is present in their nasal canal. On examination soft polyps may be observed on the nose or eye. These polyps are pink to deep red, are sessile or pedunculated, and are often described as strawberrylike in appearance¹. Since the polyps of rhinosporidiosis are vascular and friable, they bleed easily upon manipulation. Differential diagnoses of such masses in the nose include allergic polyps, mucoceles and malignancies.

Diagnosis is made by identifying the typical structures of *R seeberi* directly on microscopic examination. This includes examination of smears of macerated tissue or histology of prepared biopsy sections.

The organism can be observed with typical fungal stains (eg, Gomori methenamine silver [GMS], periodic acid-Schiff [PAS]), as well as with standard hematoxylin and eosin (H&E) staining^{3,4}. Smears can also be observed with potassium chloride (KOH) preparation^{1,2}.

Rhinosporidiosis is not responsive to medical treatment. Treatment of patients with a year long course of dapsone has been reported, but no controlled studies have been performed³. The treatment of choice is surgical excision^{1,3}. Complications of the disease include extremely rare, life-threatening dissemination, local secondary bacterial infection, and recurrence^{1,3,4}. Prognosis is excellent with complete excision. These diseases were seen in Malaysia in the 1960s prior to the rapid urbanization when the economy was mainly agriculture based. Since then however it is rarely seen and even then usually in migrant workers from the subcontinent. The increasing numbers of these workers in Malaysia brings with it numerous challenges in healthcare not least of which are the reappearance of uncommon conditions which require increased awareness among healthcare professionals.

REFERENCES

1. Mackay IS, Bull TR. Scott-Brown's Otolaryngology, 6th Ed, Butterworth-Heinemann, 1999; 4/8/39-40.
2. Lasser A, Smith HW. Rhinosporidiosis. Arch Otolaryngol 1976; 102(5): 308-10.
3. Fredricks DN, Jolley JA, Lepp PW, *et al*. Rhinosporidium seeberi: a human pathogen from a novel group of aquatic protistan parasites. Emerg Infect Dis 2000; 6(3): 273-82.
4. Mohan H, Chander J, Dhir R, Singhal U. Rhinosporidiosis in India: a case report and review of literature. Mycoses 1995; 38(5-6): 223-5.