

Sinonasal Malignant Melanocytic Melanoma: A Rare Case Report

L Pathma, MBBS, R Philip, MMed(ORL-HNS), S Harvinder, MMed(ORL-HNS), S Manjit, D.C.P.*

Department of Otorhinolaryngology, Hospital Ipoh, Jalan Hospital, 30450 Ipoh, Perak, *Department of Pathology, Hospital Ipoh, Jalan Hospital, 30450 Ipoh, Perak

SUMMARY

Malignant melanocytic melanoma is a rare sinonasal malignancy. We present a case report of an elderly lady who presented with epistaxis and intranasal polyps. Computed tomography revealed soft tissue mass in the oropharynx, nasopharynx, left ethmoid and entire maxillary sinus. The mass was removed via endoscopic medial maxillectomy. Histopathology examination revealed sinonasal melanocytic malignant melanoma. At present 17 months post-operatively she is symptom free with no recurrence and under regular follow up.

KEY WORDS:

Epistaxis, Nasal polyps, Sinonasal malignant melanocytic melanoma, Elderly

CASE REPORT

An 80 year Malay lady presented with complaints of intermittent nasal bleeding and blockage of a few months duration. She had no symptoms of pain, rhinorrhoea, or anosmia.

Endoscopic examination showed a polypoidal growth in the left nostril which was extending to the nasopharynx and entering the right posterior choanae. The polyps did not bleed on touch. The working diagnosis at this time was an antrochoanal polyp or inverted papilloma. Biopsy was taken and it revealed malignant melanocytic melanoma.

Computed tomography revealed a soft tissue mass in the oropharynx with some extension into the nasopharynx, posterior nasal spaces, left ethmoid sinus and left nasal cavity. Both fossa of rosenmuller were obliterated. The left maxillary sinus was also entirely occupied by the mass. Few lymph nodes were seen in the left posterior triangle of the neck which were of insignificant size i.e, less than 1cm and clinically not palpable. There was no bony erosion or extension into the brain and or lung metastasis (Fig. 1). She was staged as T₃ N₀ M_x from the above evidence.

The mass was excised endoscopically. A medial maxillectomy was done due to the extent of the polypoidal growth. Macroscopic examination showed multiple fragments of greyish, brownish tissue. On microscopic examination, the tumour tissue was composed of closely packed large polygonal cells with markedly pleomorphic nuclei containing

single to multiple prominent nucleoli. In areas, the tumour cells were spindle shaped. Some of the tumour cells contained melanin. The tumour cells reacted strongly with immunohistochemical staining for anti-S-100 protein(Fig.2a), HMB-45 (Fig.2b) and antivimentin. Post-operative histopathologic examination was consistent with the biopsy histology.

At 19 months post operative period the patient is well and symptom free. She is able to do her daily activities at home. Her recent endoscopic examination does not show any evidence of locoregional recurrence.

DISCUSSION

Sinonasal malignant melanocytic melanoma is a rare malignancy^{1,2}. It accounts for less than 1% of all malignant melanomas and has a 5-year survival rate of 0% to 30%¹. It occurs more commonly in the nasal cavity followed by septum, inferior turbinate, lateral nasal wall and sinuses². Involvement of the paranasal sinuses is rare. In the event of paranasal sinus involvement, the maxillary sinus is more commonly involved¹. The age of presentation is usually in the 6th to 8th decade of life as seen in this particular patient. Patients may present with either nasal blockage, epistaxis or facial pain.

Magnetic resonance imaging (MRI) is said to be better at diagnosing malignant tumours but was not done in this patient as we had a biopsy report to establish the diagnosis. Furthermore, MRI at our centre has a long waiting period.

There are a few staging systems for malignant melanoma. The New Melanoma staging system has been used since year 2002. It is comparable with the 1997 American Joint Committee on Cancer (AJCC). It takes into account 1) the primary tumour thickness, 2) ulceration, 3) number of metastatic lymph nodes, 4) micrometastasis, 5) distant metastatic disease and 6) serum lactodehydrogenase levels. The Clark's level of invasion is based on resection of the entire lesion but does not take into consideration nodal involvement. Another staging system is the Breslow's depth of invasion. It is based on measurement of tumour invasion of dermis using micrometer on the microscope. The last type of staging is the clinical staging of melanoma which has spread beyond the primary tumour or which do not have adequate tissue for histopathologic examination.

This article was accepted: 27 February 2008

Corresponding Author: Pathma Letchumanan, A-7-1, La Grande Kiara, No 11, Jalan Duta Kiara, Mont Kiara, 50480 Kuala Lumpur

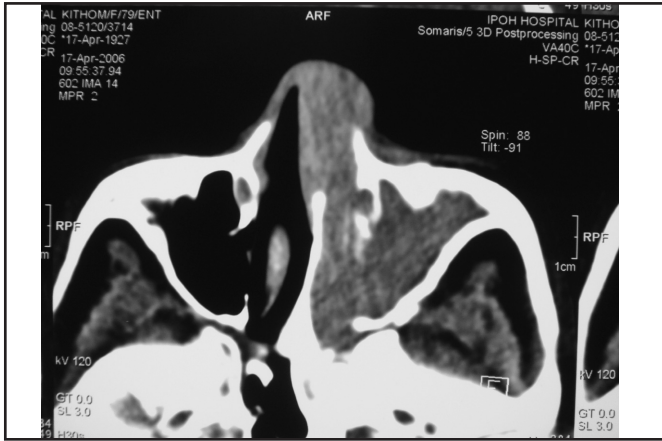


Fig. 1: CT Scan showing ill-defined enhancing mass in the left nasal cavity, nasopharynx and left maxillary sinus.

Diagnosis is made by histopathological examination and immunohistochemical staining. It is positive if it stains for anti-S-100 protein, HMB-45 and antiviimentin³. Sinonasal melanoma differs from cutaneous melanoma in its morphological presentation. Prasad *et al*³ in a study comparing sinonasal pseudostratified, ciliated columnar respiratory mucosa with oropharyngeal stratified squamous mucosa, found that the oral melanomas are more likely to be flat and thin, amelanocytic and may be detected at a noninvasive or early invasive stage. They are also more frequently desmoplastic and neuroinvasive than melanomas arising from respiratory mucosa. Sinonasal melanomas are usually pigmented, large, thick, polypoidal, ulcerated, necrotic, and deeply infiltrative tumours with a slightly higher tendency to infiltrate blood vessels. They frequently contain undifferentiated, small, round, blue cell component and display pseudopapillary architecture. The study however concludes that the clinical outcome was slightly but not significantly worse in sinonasal melanomas.

Surgery is the mainstay for treatment of melanocytic malignant melanoma. The tumour can be approached by either open or endoscopic techniques. The open approach is via lateral rhinotomy. This technique offers direct visualisation of the extent of the tumour and better control of hemostasis. It offers complete tumour excision. The endoscopic approach is currently the preferred technique as it offers less morbidity compared to the open approach. With more advanced endoscopic instruments, even tumours which are aggressive and extensive as in this case can be excised with possible curative surgical intention with less morbidity. Similar endoscopic resection is now being done for other intranasal tumours like hemangioma⁴.

The newer endoscopic approach was chosen for this patient for reasons to reduce the morbidity of open approach and the increased anaesthetic risk related to her age. Therapeutic neck dissection was not done as the nodes in the posterior triangle was of insignificant size, less than 1cm and we adopted a wait and watch method. Ideally therapeutic neck dissection should be done in the presence of neck nodes to

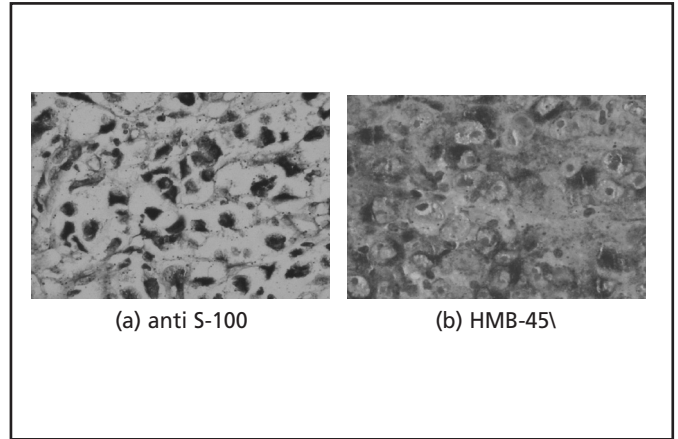


Fig. 2: Immunohistochemical staining for anti S-100 protein (a) and HMB-45(b)

reduce the risk of locoregional recurrence. The patient has so far remained free of locoregional recurrence and thus this approach could be a suitable alternative to open approaches for curative surgical intentions.

The role of postoperative radiotherapy has been studied for local control and survival. Temam *et al*⁵ reported 69 patients confirmed with primary mucosal melanoma, treated at the Institute Gustave-Roussy between 1979 to 1997 with either surgery alone (30 patients) or combined postoperative radiotherapy (39 patients). Patients who received postoperative radiotherapy were more likely to have T3-T4 tumours (44% vs 17%) and positive cervical nodes (33% vs 13%) compared with those treated with surgery alone. Patients had follow-up from 8-384 months with a median 3.8 years. Local control rates were as follows: surgery alone, 8 of 30 patients (26%), surgery with postoperative radiotherapy, 24 of 39 patients (62%), and overall, 32 of 69 patients (46%). The survival rates were as follows: surgery alone had a median local disease-free survival period of 9 months and surgery with postoperative radiotherapy had a median survival period of 33 months. Univariate analysis showed postoperative radiotherapy was associated with better local disease-free survival. In our patient, we had an adequate surgical margin by endoscopic excision and therefore didn't send her for postoperative radiotherapy.

REFERENCES

1. Kardon DE, Thompson L D R. Sinonasal mucosal malignant melanoma: Report of an unusual case mimicking schwannoma. *Ann Diagn Pathol* 2000; 4(5): 303-7.
2. Nakaya M, Mochiki M, Takeuchi S. Malignant melanoma of nasal cavity: report of 16 Japanese patients. *Auris Nasus Larynx* 2004; 31(3): 233-37.
3. Prasad ML, Busam KJ, Patel SG. Clinicopathologic Differences in Malignant Melanoma Arising in Oral Squamous and Sinonasal Respiratory Mucosa of the Upper Aerodigestive Tract. *Arc Path Lab Med* 2003; 127(8): 99-1002.
4. Ahmad R, Norie A. Endonasal Endoscopic Resection of Intranasal Haemangioma. *Med J Malaysia* 2006; 61 (5): 644-46.
5. Temam S, Mamelle G, Marandas P. Postoperative radiotherapy for primary mucosal melanoma of the head and neck. *Cancer* 2004; 103(2): 313-19.