

Powered Endoscopic Dacryocystorhinostomy with Mucosal Flaps Without Stenting

S Harvinder, MMed (ORL-HNS), S Rosalind, MMed (ORL-HNS), R Philip, MMed (ORL-HNS), S Mallina, MBBS, S Gurdeep, MS (HNORL)

Department of ENT, Hospital Ipoh, Jalan Hospital, 30990, Ipoh, Perak, Malaysia

SUMMARY

Dacryocystorhinostomy (DCR) is a procedure performed to drain the lacrimal sac in cases of nasolacrimal duct obstruction or in chronic dacryocystitis. It can be performed externally or endoscopically. This is a prospective, nonrandomized study involving twenty-two consecutive patients (16 Females and 6 Males; mean age 45.54y; range 18-74y) who presented to the DCR clinic with epiphora secondary to nasolacrimal duct obstruction and recurrent infection. All patients underwent primary powered endoscopic DCR. A total of 24 procedures were performed using a standardized surgical technique. Post-operatively, symptom evaluation and endoscopic assessment of the newly created lacrimal ostium were done. Twenty-two of the 24 DCR's were patent after a mean follow-up of 21.5 months, yielding a success rate of 91.66%. Patency was assessed by symptomatic evaluation and endoscopic visualization at each post-operative visit. Two patients had complications, one orbital fat exposure and the other secondary haemorrhage. The two failures were due to synechiae formation. Therefore, powered endoscopic DCR with mucosal flaps without stenting has a success rate comparable to that achieved with stents and external DCR.

KEY WORDS:

Endoscopic dacryocystorhinostomy, Epiphora, Lacrimal stents

INTRODUCTION

Caldwell¹ was the first to describe an endonasal approach to treat nasolacrimal duct obstruction (NLDO). These attempts were abandoned because of technical limitations in terms of poor visualization of the surgical site. Therefore the popularity of intranasal dacryocystorhinostomy (DCR) was limited throughout the twentieth century. External (DCR) was then popularized and has been the treatment most commonly used for the last century with a few modifications. With the advent of fiberoptic endoscopes and rigid endoscopic techniques in the late 1980s and early 1990s, there had been renewed interest over the past decade in endoscopic (DCR)^{2,3}.

Rates for success for endoscopic dacryocystorhinostomy (DCR) ranges from 70%⁴ to 95%^{5,6,7}. These results are similar to those achieved with external DCR^{8,9}. The key to the improved success rates achieved with endoscopic DCR is to attempt to replicate the external procedure as closely as possible. The creation of a large bony rhinostomy and

mucosal flaps is the key to success^{10,11}. In order to achieve complete lacrimal sac exposure and correct sitting of the rhinostomy, the understanding of the nasal anatomy and its relationship to the lacrimal sac is vital^{12,13}. Studies of intranasal anatomy of the lacrimal sac has shown that the rhinostomy needs to be larger and higher on the lateral wall than previously thought, as a result, the upper half of the sac is behind the thick bone of the frontal process of the maxilla^{12,13}. Full sac exposure requires extensive dissection of the frontal process of the maxilla either by using a powered drill or chisel.

The size of the lacrimal ostium created during endoscopic DCR is paramount to the success of this surgery¹⁴. Another key factor is the need for mucosal preservation^{12,13}. Nasal mucosa is preserved so that it can be fashioned to the lacrimal flaps created to achieve mucosal apposition of the marsupialized sac and of the nasal mucosa.

Here, a standard endoscopic surgical technique is described¹⁰, but without stents being applied and results in patients in whom the procedure was performed is presented.

MATERIALS AND METHODS

A prospective, nonrandomized study of twenty-two consecutive patients who underwent primary endoscopic DCR using powered instrumentation without stenting in our center since April 2005 to December 2006 were included in this study. Prospective data collected includes the patients age, sex, affected side, symptoms, operative experience, and follow-up results.

Pre-operatively, all patients were seen in the lacrimal clinic in the presence of an ophthalmologists. All patients undergo a standard rigid nasal endoscopy. This procedure allows septal deviation to be detected and any additional nasal or sinus pathologic conditions to be evaluated. At the same time, the ophthalmologists, performs a thorough examination of the lacrimal system that includes probing and syringing. All patients also routinely undergo dacryocystography to establish patency of the the lacrimal system

The surgical technique used in this study has been extensively described by PJ Wormald¹⁰. The only difference is that no stents was used to keep the newly formed lacrimal ostium patent at the end of the procedure.

This article was accepted: 14 July 2008

*Corresponding Author: Harvinder Singh, Consultant ENT Surgeon, Department of ENT, Hospital Ipoh, Jalan Hospital, 30990 Ipoh, Perak
Email: harvindrsran@hotmail.com*

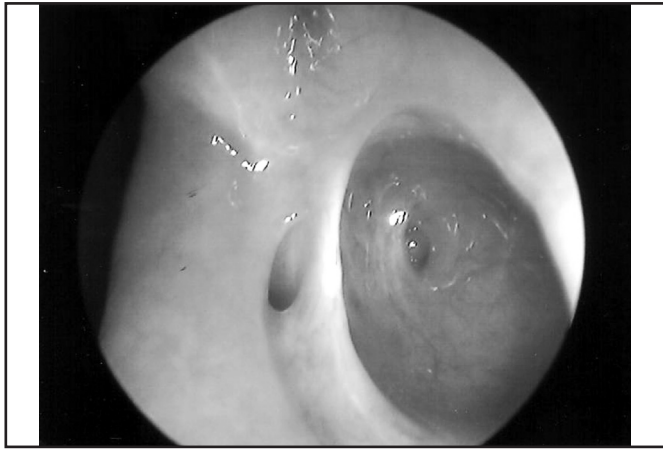


Fig. 1: Left Lacrimal ostium 2 years post-operatively.

The patients were discharged the next day with a broad spectrum antibiotic, a decongestant nasal spray and Chloramphenicol eye drops for a week. Patients were reviewed in the clinic at regular intervals. Size of the ostium and patency of the lacrimal system was assessed by symptomatic evaluation and endoscopic visualization at each post-operative visit (Figure 1). All patients were followed-up in the lacrimal clinic.

RESULTS

Twenty-two consecutive patients (16 Females and 6 Males; mean age 45.54y; range 18-74y) who presented to the DCR clinic underwent primary powered endoscopic DCR. A total of 24 procedures were performed. All patients presented with epiphora pre-operatively. Thirteen patients underwent left-sided DCR, seven right-sided DCR, and two bilateral DCR. Six patients required septoplasty during the DCR procedure. Two patients had complications, one orbital fat exposure and the other secondary haemorrhage. The two failures were due to synechiae formation. All patients were discharged the day after surgery.

Twenty-two of the 24 DCR's were patent after a mean follow-up of 21.5 months, yielding a success rate of 91.66%. Patency was assessed by symptomatic evaluation and endoscopic visualization at each post-operative visit.

DISCUSSION

Endoscopic DCR has many advantages over external DCR. The main advantages are avoidance of facial scarring, non-division of the medial canthal ligament and the preservation of the pump action of the lacrimal sac of the orbicularis oculi muscle^{7,9}. In powered endoscopic DCR with full lacrimal sac exposure, the results achieved is comparable with the external method^{8,9}. The size of the bony ostium and the extent of the sac exposure are important factors in determining post-operative patency of the newly created ostium^{8,9,10,14}.

Wormald *et al*¹⁰ had demonstrated that approximately two thirds of the lacrimal sac is above the axilla of the middle turbinate. Therefore during DCR surgery, in order to accomplish complete sac exposure, a large amount of thick bone over the axilla of the middle turbinate and the lateral wall of the agger nasi has to be removed¹⁰. Removal of this thick bone is best achieved with a diamond burr because it allows rapid bone removal while protecting the lining of the

sac from damage¹⁰. The common canaliculus should be identified as a landmark for adequate sac exposure once the lacrimal sac is opened, because at least two thirds of the sac is below this opening¹⁰.

Once the lacrimal sac has been opened it is important to achieve primary intention healing between the edges of the sac and the nasal mucosa. The U-shaped flap fashioned at the end of the procedure allows for primary intention healing to occur¹⁰. In the posterior superior region of the lacrimal sac, apposition with the nasal mucosa is difficult so the exposed agger nasi cell mucosa is routinely opened and apposition between this mucosa and the lacrimal mucosa is achieved in this area¹⁴. This flap is further stabilized by positioning two small cut stripes of merogel along the posterior and inferior edges of the junction between the sac and nasal wall. This apposition of sac mucosa to nasal mucosa is similar to what is achieved in external DCR by suturing of the anterior and posterior sac flaps to the nasal mucosa¹⁰.

At the end of the procedure, no stents were left behind. This is because powered endoscopic DCR accomplishes three principles that are, achieving full lacrimal sac exposure, marsupialization of the entire sac into the lateral nasal wall, and primary intention healing between the sac and nasal mucosa. The success rate in our series of powered endoscopic DCRs with total sac exposure with primary intention healing without stents was 91.66% which is comparable with results achieved by powered endoscopic DCRs with stents and external DCR^{5,6,7,8,9,10,15,16}. In conclusion powered endoscopic DCR with mucosal flaps without stenting has a success rate comparable to that achieved with stents and external DCR.

REFERENCES

1. Caldwell GW. Two new operations for obstruction of the nasal duct, with preservation of the canaliculi, and with an incidental description of a new lacrimal probe. *Am J Ophthalmol* 1893; 10: 189-93.
2. Benger R, Forer M. Endonasal dacryocystorhinostomy-primary and secondary. *Aust N Z J Ophthalmol* 1993; 21(3): 157-59.
3. McDonogh M, Meiring JH. Endoscopic transnasal dacryocystorhinostomy. *J Laryngol Otol* 1989; 103: 585-87.
4. Hehar SS, Jones NS, Sadiq A, Downes RN. Endoscopic holmium: YAG laser dacryocystorhinostomy- safe and effective as a day-case procedure. *J Laryngol Otol* 1997; 111: 1056-59.
5. Metson R, Woog JJ, Puliafito CA. Endoscopic laser dacryocystorhinostomy. *Laryngoscope* 1994; 104: 269-74.
6. Sprekelsen MM, Barberan MT. Endoscopic dacryocystorhinostomy: surgical technique and results. *Laryngoscope* 1996; 106: 187-89.
7. Weidenbecher M, Hosemann W, Buhr W. Endoscopic endonasal dacryocystorhinostomy: results in 56 patients. *Ann Otol Rhinol laryngol* 1994; 103: 363-67.
8. Welham RA, Wulc AE. Management of unsuccessful lacrimal surgery. *Br J Ophthalmol* 1987; 71: 152-57.
9. Hartikainen J, Grenman R, Puukka P, Seppa H. Prospective randomized comparison of external dacryocystorhinostomy and endonasal laser dacryocystorhinostomy. *Ophthalmology* 1998; 105: 1106-13.
10. Wormald PJ. Powered endonasal dacryocystorhinostomy. *Laryngoscope* 2002; 112: 69-71.
11. Tsirbas A, Wormald PJ. Mechanical endonasal DCR with mucosal flaps. *Am J Ophthalmol* 2003; 135(1): 79-86.
12. Duffy MT. Advances in lacrimal surgery. *Curr Opin Ophthalmol* 2000; 11: 352-56.
13. Wormald PJ, Kew J, van Hasselt CA. The intranasal anatomy of the nasolacrimal sac in endoscopic dacryocystorhinostomy. *Otolaryngol Head Neck Surg* 2000; 123: 307-10.
14. Mann BS, Wormald PJ. Endoscopic assessment of the dacryocystorhinostomy ostium after endoscopic surgery. *Laryngoscope* 2006; 116: 1172-74.
15. Tsirbas A, Wormald PJ. Mechanical endonasal dacryocystorhinostomy with mucosal flaps. *Otolaryngol Clin N Am* 2006; 39: 1019-36.
16. Wormald PJ. Powered endoscopic dacryocystorhinostomy. *Otolaryngol Clin N Am* 2006; 39: 539-49.