

The TB – Crohn's Affair – A Never Ending Dilemma

S Praveen, MD, J Razman, MS

Surgical Department, Hospital Universiti Kebangsaan Malaysia, Cheras, 56100 Kuala Lumpur, Malaysia

SUMMARY

An 80 year old lady presented with signs and symptoms of sub-acute intestinal obstruction which failed conservative management. CT scan abdomen revealed circumferential ileum thickening with proximal bowel dilatation. Laparotomy and segmental resection was done. Pathological findings were suggestive of chronic granulomatous ileitis with differential of Crohn's disease and gastrointestinal tuberculosis. The patient was presumed to have gastrointestinal tuberculosis and commenced on anti tuberculosis treatment despite inconclusive evidence for confirmation and showed marked clinical improvement.

KEY WORDS:

Abdominal tuberculosis, Intestinal tuberculosis

INTRODUCTION

Gastrointestinal tuberculosis is a known cause of intestinal obstruction. In Malaysia, the incidence pulmonary and extra-pulmonary tuberculosis manifestations are high. Although the clinical presentation of a patient may be suggestive of gastrointestinal tuberculosis, the pathological diagnosis is difficult as there are no pathognomonic features to suggest this disease. This is a case report of an 80 year old lady who presented with intestinal obstruction secondary to presumed gastrointestinal tuberculosis. However the pathological specimens were inconclusive for establishment of the diagnosis. A review of reports in differentiating gastrointestinal tuberculosis from other disease such as Crohn's are discussed.

CASE REPORT

An 80 year old Chinese lady presented with central abdominal pain of one day duration associated with fever for one week, loss of appetite for three weeks and had not opened her bowels for three days but was passing flatus. On examination, she had fever and mild dehydration but other vital signs were normal. Her abdomen was mildly distended with tenderness at the upper half and no mass palpable. Her white cell counts were elevated but other parameters were normal. An abdominal radiograph showed dilated loops of small bowel mainly in the left side of the abdomen with minimal air in the rectum. She was diagnosed with sub-acute intestinal obstruction possibly from a right sided colon tumour. A Computer Tomography (CT) of the abdomen revealed circumferential thickening of terminal ileum resulting in proximal obstruction with multiple lesions in segment 4 a, 6, 7 and 8 of liver which were likely cyst. The radiological diagnosis was either lymphoma or chronic

infective inflammatory mass. An exploratory laparotomy was performed. It revealed three segments of indurated and narrowed ileum located at 10cm, 30cm and 50cm from the terminal ileum with adjacent mesentery thickening and lymph nodes. The proximal small bowels were dilated. There were numerous whitish nodules along the small bowel and parietal peritoneum with a solitary liver nodule in segment 6.

Segmental resection of the abnormal ileum with primary anastomosis was performed. Macroscopic histopathology showed thickened mesenteric fat (Fig 1 a) with numerous tiny yellowish pearl like nodules over the serosal surface. The intestinal wall was thickened with luminal narrowing. Microscopically there was gut wall fibrosis, transmural inflammation with mixed inflammatory infiltrate and non-caseating granuloma. The inflammation was most in mucosa and submucosa with mucosal ulceration and fissures seen. There were no fistulas but numerous multi-nucleated giant cells seen surrounded by epithelioid granuloma, lymphocytes and plasma cells.

No obvious caseation was seen (Fig 1b). Ziehl-Neelson staining was negative, with no fungal bodies seen and negative for malignancy. The final pathological diagnosis was granulomatous ileitis with differential diagnosis of Tuberculosis, Crohn's disease, Sarcoidosis and Yersinia enterocolitica. However based on clinical presentation, intraoperative finding and certain pathological features, she was diagnosed with gastrointestinal tuberculosis and anti tuberculosis treatment was commenced.

DISCUSSION

Gastrointestinal tuberculosis can occur anywhere from mouth to anus and its clinical manifestations are dependent on the organ involved. The differential diagnosis are Crohn's disease, lymphoma, carcinoma, Yersinia infection and amoebiasis. It is the similarity of presentation between gastrointestinal tuberculosis and Crohn's disease particularly in the elderly which poses a diagnostic challenge. Patel et al in his study reported that 29.6% of patients are treated based on presumptive diagnosis of tuberculosis. Four percent of patients treated with presumptive diagnosis turned out to have Crohn's disease². Therefore the definitive diagnosis is crucial because their managements differ.

Onset of symptoms for gastrointestinal tuberculosis are usually insidious, except for cases which present acutely due to complications. Our patient had a short history of pain with partial bowel obstruction which is present in 90-100% of patients with gastrointestinal tuberculosis¹. Fever is seen in

This article was accepted: 9 June 2008

Corresponding Author: Praveen Singam, Surgical Department, Hospital Universiti Kebangsaan Malaysia, Jalan Yaacob Latif, Bandar Tun Razak, 53000 Cheras, Kuala Lumpur Email: drpsingam@gmail.com

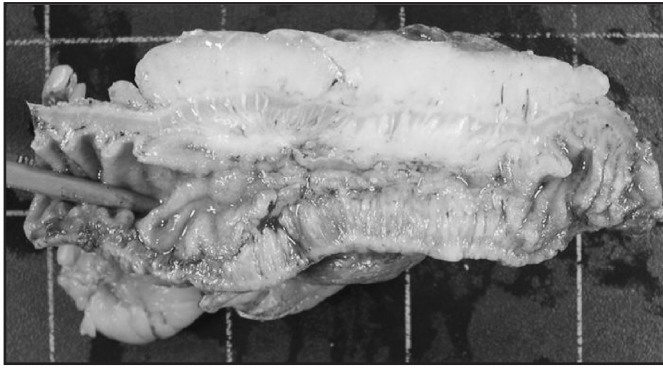


Fig. 1a: Cut segment of affected small bowel with thickened mesenteric fat, circumferential lumen narrowing and thickened bowel wall

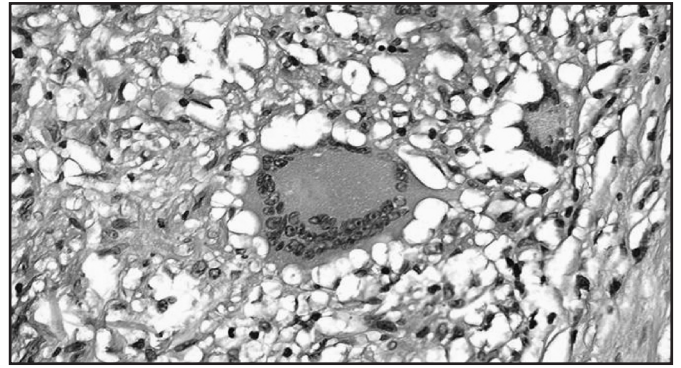


Fig. 1b: Microscopic appearance of non – caseating granuloma with surrounding inflammatory cells from affected bowel.

35-50% of patients while weight loss and change of bowel habits are noted in 66% and 20% of patients with gastrointestinal tuberculosis. An elevated erythrocyte sedimentation rate is present in 90% of patients. A purified protein derivative test is positive in 70 -86% of patients¹. Both tests were negative for our patient. The chest radiograph did not reveal any abnormality. Only 35% of patients with gastrointestinal tuberculosis to have a positive chest radiological finding¹.

Complications of gastrointestinal tuberculosis include obstruction (15-60%), fistulization (2-30%), perforation (1-15%) and haemorrhage (2%)¹. These complications can occur similarly in Crohn's disease. Intra operatively, there was thickened mesenteric fat, studding of the peritoneum and the small bowel with whitish nodules which can be present in Crohn's disease and tuberculosis. Segmental bowel involvement is suggestive of skip lesions in Crohn's disease. There were also multiple mesenteric lymph nodes and a hepatic nodule which incline towards a diagnosis of gastrointestinal tuberculosis. Hepatic tuberculosis occurs in 50-80% of patient dying of pulmonary tuberculosis either in the diffuse form or the nodular form which is characterized by tubercles coalescing to form either a large tumour like tuberculoma or abscess³.

Findings which would suggest Crohn's disease (which were not present in our patient) are the presence of internal or cutaneous fistula, skip lesions in bowel, cobblestone appearance of mucosa, perianal disease and other extracolonic manifestations.

Histology specimens revealed areas of non caseating granuloma, epitheloid cells, fissures and microabscess. Acid fast bacilli (AFB) were not detected which are consistent with Crohn's disease. Other features of Crohn's disease are presence of fistula, a transmural involvement which is more severe in submucosa and subserosal and granuloma without necrosis. Tuberculosis would have caseating granulomas, without fissures and fistula and involvement of muscularis externa. Caseating granuloma and a positive AFB smear are present in 66% and 29% respectively in gastrointestinal

tuberculosis patients². The detection of granulomas in the mesenteric lymph nodes without any in intestine is an important pathological finding in tuberculosis, while in Crohn's, mesenteric lymph nodes may not have granuloma if the intestinal wall is devoid of them.

Anti tuberculosis was commenced based on several factors. Firstly, this was an elderly patient in her 80's, whereas Crohn's disease usually occurs between 30-40 years. Secondly, findings during surgery of segmental small bowel involvement with presence of hepatic nodule and peritoneal studding suggest tuberculosis. Thirdly, tuberculosis is endemic in Malaysia and Crohn's disease is relatively rare.

The patient was given Isoniazide, Rifampicin, Pyrazinamide and Ethambutol. Most series report a treatment duration of 9 to 24 months. However more recent reports showed that six months therapy is adequate¹. Our patient has shown marked clinical improvement after starting treatment.

CONCLUSION

The diagnosis of gastrointestinal tuberculosis is difficult because of its varied clinical presentation, non specific investigative tools and its profound similarities with Crohn's disease even in pathological specimens. Much have been reported about the salient features in the history, clinical finding and investigations to distinguish them apart but each case still poses challenge in diagnosis and administrating the appropriate treatment. However with recent advancements and evidence based reports, we are more likely now to make an accurate diagnosis than our predecessors.

REFERENCES

1. Karen D, Richard L. Intestinal Tuberculosis: Return of an Old Disease. *Am J Gastroenterol* 1998; 93: 692-96.
2. Patel N, Deepak A, Subhash A, Rajiv B, Pramod K, Snehanu P, Parjit G. Gastrointestinal Luminal Tuberculosis: Establishing the Diagnosis. *J Gastroentr Hepato* 2004; 19: 1240-46.
3. Faylona JMV, Chung SCS. Abdominal Tuberculosis Revisited. *Ann Coll Surg* 1999; 3: 65-70.
4. Aziah A M. Tuberculosis in Malaysia: Combating the Old Nemesis. *Med J Mal.* 2004; 59 (1).