

# Ophthalmomyiasis from *Chrysomya bezziana* (Screwworm Fly)

M Alhady, MD\*, K Zabri, MD\*\*, C N Chua, FRCOpath\*

\*The Ophthalmology Unit, Universiti Malaysia Sarawak (UNIMAS), Lot 77, Seksyen 22 Kuching Town Land District, Jalan Tun Ahmad Zaidi Adruce, 93150 Kuching, Sarawak \*\*The Eye Department, Sarawak General Hospital, Kuching, Sarawak, Malaysia

## INTRODUCTION

Ophthalmomyiasis refers to infestation of the eye by dipterous fly larvae such as *Chrysomya bezziana*. *Chrysomya bezziana* is also known as old world screw worm; it is an obligatory parasite of the wound and found mostly in tropical and subtropical areas of the world. The sequelae of ophthalmomyiasis may range from minor irritation to blindness and even death. Treatment of ophthalmomyiasis involves removal of the larvae.

## CASE REPORT

A previously well 9-year-old boy from a border town with Kalimantan, Indonesia, some 100km from our hospital, complained of a two-week history of bloody discharge in his right ear. The local doctor noted ulceration of the right ear canal and the presence of live maggots. He was referred to our otolaryngologist who removed 45 maggots from the right middle ear cavity under general anaesthesia. While recovering at the hospital, the patient's right eye was noted to be red. He was referred to our eye department. Apart from a right red eye, his vision was normal. Slit-lamp examination showed a breach in the superonasal bulbar conjunctiva and a live maggot could be seen lying deep in the wound. Attempt to remove the worm was unsuccessful as the patient was unable to cooperate. Under general anaesthesia, the conjunctival wound was extended to expose the maggot

(Figure 1a) which was removed whole with a pair of forceps. The worm measured 12mm (Figure 1b). Based on the shape, mouth and tail part of the maggot, it was identified as the larva of *Chrysomya bezziana* (screwworm fly, Figure 2).

## DISCUSSION

Myiasis is coined from the Greek word 'myia' denoting fly. It refers to the infestation of tissues by the larvae (maggots) of diptera (two-winged) flies. The condition is well recognised in animals but rare in humans<sup>1,2</sup>. Cases of human myiasis have been reported in various parts of the world and could be attributed to one of the three dipteran families: Oestriade, Calliphoridae and Sarcophagidae.

In South-East Asia, animal myiasis is endemic and the main causative agent is *Chrysomya bezziana*, also known as screwworm fly of the Old World. This fly belongs to the Calliphoridae family and causes obligatory myiasis (it requires a living host for the development of the larval stages). It infests mainly domestic animals and may cause great losses in livestock industry if not treated rapidly<sup>3</sup>.

Screwworm infestation is transmitted by the female fly that lays her eggs on a superficial wound, but occasionally on unbroken soft skin, especially if it has blood or mucous discharge on its surface. Eggs are deposited in batches of 150

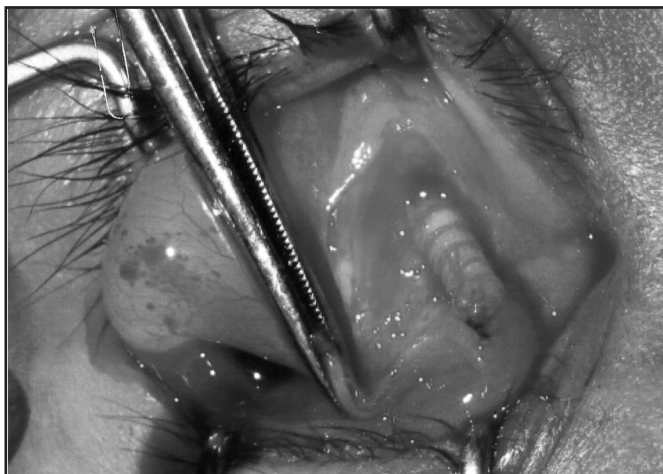


Fig. 1: Screwworm fly (*Chrysomya bezziana*) partially extracted from the subconjunctival space and b. The carcass of the extracted screwworm fly (*Chrysomya bezziana*) larva measuring 12 mm.

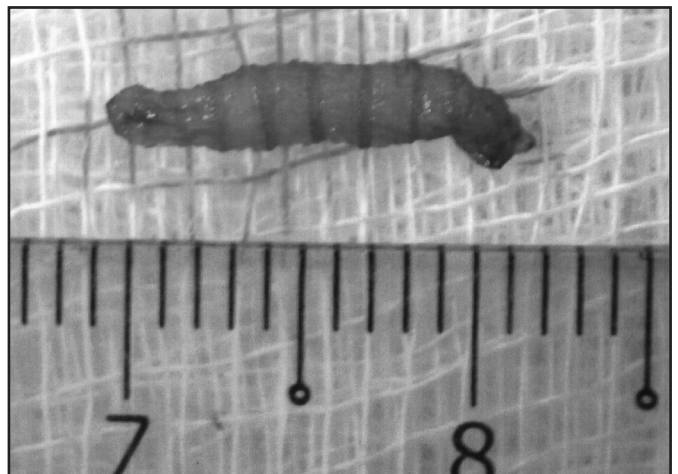

Fig. 2: An adult screwworm fly (*Chrysomya bezziana*).

This article was accepted: 8 July 2008

Corresponding Author: Chua Chung Nen, Ophthalmology Unit, Universiti Malaysia Sarawak (UNIMAS), Lot 77, Seksyen 22 Kuching Town Land District, Jalan Tun Ahmad Zaidi Adruce, 93150 Kuching, Sarawak

to 500 and hatch in about 15 hours. The larval bodies, measuring 10 to 15mm are armed with broad, encircling bands of spines. The larvae feed on blood and serum and burrow deep into the tissue with their mouth-hooks causing considerable destruction. Infested wounds often attract other female screwworms resulting in multiple infestations. After feeding for 5 to 7 days, the larvae leave the wound and fall to the ground where they burrow and pupate for one week or more to emerge as adult flies. The life cycle from egg to egg takes about 24 days<sup>4</sup>.

Both otomyiasis and ophthalmomyiasis from screwworms are rare and there are only a handful of reported cases<sup>5</sup>. Our case is unusual because of the simultaneous involvement of two sites. Otomyiasis may occur from neglected chronic lesions such as chronic suppurative otitis media with poor personal hygiene. The destruction of the auditory meatus can lead to deafness, meningitis and even death. Ophthalmomyiasis typically occurs in demented and debilitated patients with chronic eye diseases such as eyelid tumours<sup>6</sup>. In our patient, the concurrent ophthalmic infestation by a single screwworm is likely to be the result of migration of the screwworm from the aural cavity into the conjunctiva. Depending on the

destruction caused, screwworm can cause external, internal or orbital ophthalmomyiasis. External ophthalmomyiasis involves the eyelid and conjunctiva, orbital ophthalmomyiasis the orbital content, and internal ophthalmomyiasis the intraocular spaces. The treatment of ophthalmomyiasis involves removal of the maggots and cleaning the lesion with saline and antibiotic solution. Prophylactic antibiotic therapy may prevent secondary infections.

#### REFERENCES

1. Chan JC, Lee JS, Dai DL, Woo J. Unusual cases of human myiasis due to Old World screwworm fly acquired indoors in Hong Kong. *Trans R Soc Trop Med Hyg.* 2005; 99(12): 914-8.
2. Bhatt, A.P., Jayakrishnan, A. Oral myiasis: a case report. *Int. J. Paediatr. Dent.* 2000; 10: 67-70.
3. Atzeni MG, Mayer DG, Spradbery JP, Anaman KA, Butler DG. Comparison of the predicted impact of a screwworm fly outbreak in Australia using a growth index model and a life-cycle model. *Med Vet Entomol.* 1994; 8(3): 281-91.
4. Goddard J. *Physician's guide to arthropods of medical importance.* 4th Edition. CRC Press 2002; 195-215.
5. Talari S, Yeganeh-Moghadam A, Dehghani R. *Chrysomya bezziana* infestation. *Arch Iran Med* 2002; 5 (1): 56-58.