

Haemangioma of the Uvula Causing Loud Habitual Snoring – A Rare Entity

*J F Thong, MRCS, **K P Pang, FRCS, *J K Siow, FRCS

*Department of Otorhinolaryngology, Tan Tock Seng Hospital, Singapore, **Consultant, Director, Pacific Sleep Centre, Paragon Medical Centre, Singapore

SUMMARY

Mucosal haemangiomas are unusual and typically involve frequently traumatised areas such as the lip, buccal mucosa and lateral borders of the tongue. Uvular haemangioma is rare and to our knowledge, has never been reported to cause obstructive sleep apnoea (OSA). We report an unusual case of uvular haemangioma causing loud habitual snoring and symptoms suggestive of OSA. This case report illustrates a rare cause of OSA and demonstrates the efficacy of surgery for obvious obstructive lesions of the pharynx.

KEY WORDS:

Haemangioma, Uvula, Obstructive sleep apnoea, Snoring

INTRODUCTION

Obstructive sleep apnoea (OSA) is a sleep disorder in which repeated episodes of airflow cessation or reduction occur as a result of upper airway narrowing and collapse. Symptoms of obstructive sleep apnoea include snoring, daytime somnolence, choking at night, as well as fatigue, poor memory and mood changes. Anatomic abnormalities commonly seen on physical examination include retrognathia, tonsillar or adenoidal hypertrophy, macroglossia and soft palate redundancy.

Haemangiomas are benign vascular anomalies that typically present in childhood and commonly involve the head and neck region. However, the uvula has very rarely been reported as the site of involvement¹ and, to the best of our knowledge, has never been reported to cause OSA. In this paper, we present the first case of a uvular haemangioma in an adult, causing symptoms suggestive of obstructive sleep apnoea.

CASE REPORT

A 30 year old Bangladeshi gentleman was referred to the ENT outpatient clinic with a long history of loud daily snoring and excessive daytime somnolence. He had been excessively tired during the day, and had an Epworth sleepiness score of 16 out of 24. The Epworth sleepiness score is derived from a self-administered questionnaire and is a subjective measurement of sleepiness experienced by the patient. A score of more than 10 is considered to be excessive sleepiness. The patient himself noted that he had a large bluish-looking uvula which his colleagues did not have. Oral examination revealed a

uvula significantly enlarged and elongated with a purplish appearance as well as several other similar purplish lesions on the soft palate (see Figure 1). The purplish lesions were soft, non-pulsatile and did not blanch. Nasal endoscopy revealed the hemangiomatous lesion to be on the nasal side of the soft palate as well. The rest of the ENT examination was otherwise unremarkable. A clinical diagnosis of obstructive sleep apnoea secondary to haemangioma of the uvula was made. The patient subsequently underwent complete en bloc excision of the haemangioma by CO₂ laser under general anaesthesia. Closure of soft palatal defect was by stitching the anterior soft palatal mucosa to the remnant posterior flap of mucosa from the nasal side of the soft palate. The patient recovered uneventfully with no post-operative velopharyngeal incompetence or any haemorrhage. He was reviewed at three months post-operatively; the patient was pleased and remained well with no further complaints of snoring or daytime somnolence (see Figure 2).

DISCUSSION

Cavernous haemangiomas are benign vascular lesions composed of a proliferation or excess of vascular channels, usually veins and capillaries. They typically present in childhood, undergo rapid growth by proliferation and then slowly involute. However, involution is often incomplete and may present with complications that require treatment². Adult-onset lesions tend to slowly enlarge over a period of months or years, and extension into underlying muscle or pressure atrophy of underlying bone may occur.

The head and the neck are common sites of haemangiomas, representing more than a third of all haemangiomas in humans². Haemangiomas can affect both cutaneous surfaces of the head and neck and also the mucosal surfaces. They are typically soft and painless. The more superficial lesions are often lobulated and blanch with pressure, whereas deeper lesions tend to impart a purplish discoloration and seldom blanch.

Haemangiomas of the oral cavity typically present at an older age and in adults, the mucosal haemangioma often arises from frequently traumatised areas such as the lip, buccal mucosa and lateral borders of the tongue³. Haemangiomas involving the uvula have rarely been reported¹ and to our knowledge, there has been no reported case of a uvular haemangioma causing loud habitual snoring.

This article was accepted: 18 September 2008

Corresponding Author: Thong Jiun Fong, #08-15, Sherwood Towers, 1, Jalan Anak Bukit, Singapore 588996

Email: jiunfong@yahoo.com

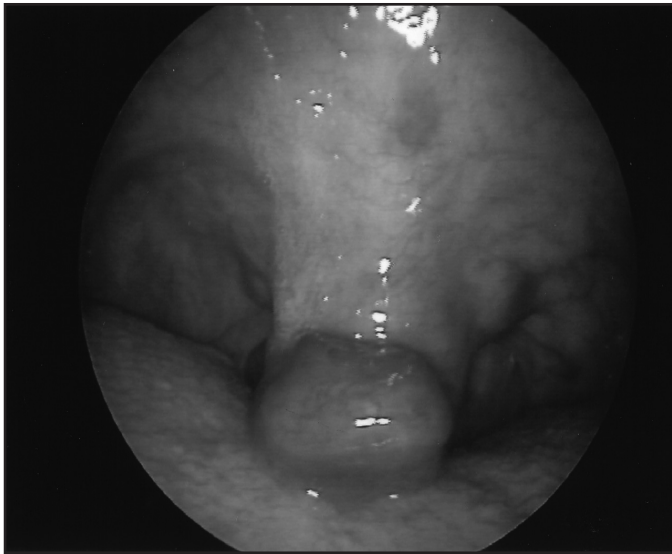


Fig. 1: Haemangioma involving the uvula and soft palate

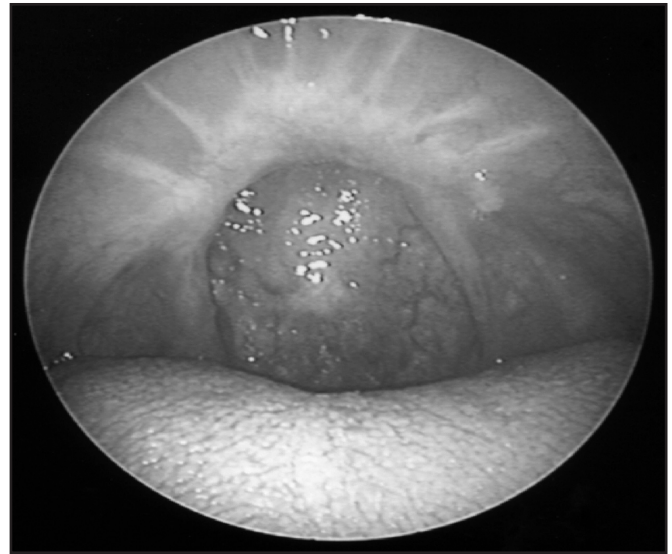


Fig. 2: Post-Operative view of Pharynx

Most true haemangiomas require no intervention, but 10-20% requires treatment because of the size, location, behaviour or degree of functional compromise. Treatment options include conservative management by monitoring, steroids, cryotherapy, sclerotherapy and surgical excision. The use of laser therapy for the treatment of haemangiomas has gained popularity. Lasers have evolved to where more selective photothermolysis can be attained rather than nonselective tissue destruction. Lasers used include the neodymium:yttrium-aluminum-garnet (Nd:YAG) laser and the carbon dioxide laser. The Nd:YAG laser has been used to treat massive haemangiomas and vascular malformations in the head and the neck. It emits beams in the near infrared region of the spectrum (1064 nm) and has deep penetration (1cm) with excellent haemostatic capability. The carbon dioxide laser which emits light in the far infrared region, with a wavelength of 10,600 nm and is mainly absorbed by water molecules, has also been used successfully to treat oral haemangiomas.

Our patient presented with loud habitual snoring and excessive daytime somnolence secondary to a uvular haemangioma and suggestive of OSA. The patient however could not afford to undergo a polysomnogram test to confirm OSA. The carbon dioxide laser was used for its haemostatic

effect on the operative wound edge and the haemangioma was totally and safely excised with minimal bleeding intraoperatively. Post-operative recovery was uneventful with no development of velopharyngeal incompetence. Excision of the lesion proved to be curative of his symptoms. Epworth score post operatively was 7 of 24. Our patient illustrates a rare cause of OSA and the efficacy of surgery for obvious obstructive lesions of the pharynx causing OSA.

CONCLUSION

With aggressive surgical cytoreduction and radiotherapy with or without chemotherapy, median survival of GBM is 62 weeks compared to 17 weeks for untreated patients. Therefore, in young patients with resectable tumour, a meticulous, yet aggressive resection followed by complete radiotherapy should be advocated to achieve a good outcome.

REFERENCES

1. Sobrinho FPG, Felix MA, do Valle AC, Lessa HA. Hemangioma of uvula: one case report. *Rev Bras Otorrinolaringol* 2003; 49(4): 571-4.
2. Waner M, Suen JY, Dinehart S: Treatment of hemangiomas of the head and neck. *Laryngoscope* 1992; 102(10): 1123-32.
3. Woods WR, Tulumello TN. Management of oral haemangioma. Review of the literature and report of a case. *Oral Surg Oral Med Oral Pathol* 1977; 44: 39.