

# Parotid Abscess: An Unusual Cause of Facial Nerve Palsy

Y Noorizan, MBBCh\*, Y K Chew, MBBS\*\*, A Khir, MS\*\*, S Brito-Mutunayagam, MS\*\*

\*Department of Otorhinolaryngology, University Kebangsaan Malaysia Medical Centre, Bandar Tun Razak 56000 Cheras, Kuala Lumpur, \*\*Department of Otorhinolaryngology, Hospital Pakar Sultanah Fatimah, 84000 Muar, Johor, Malaysia

### SUMMARY

Facial nerve palsy with a parotid mass is usually associated with malignant neoplasm of parotid gland. Its occurrence as a complication of parotid abscess is extremely rare. A literature review revealed only 16 cases of facial nerve palsy associated with suppurative parotitis or parotid abscess were reported. We present a case of deep parotid abscess which is complicated by facial nerve dysfunction. Underlying neoplasia was excluded.

### KEY WORDS:

Abscess, Parotid, Facial palsy

### INTRODUCTION

Facial nerve palsy associated with parotid gland mass is always caused by malignant neoplasm of the gland. It has been documented in benign parotid disease such as benign mixed tumours, Warthin's tumour, parotid cysts and alveolar duct malformation<sup>1</sup>. Its occurrence complicating parotitis or parotid abscess is exceedingly rare with only 16 cases found in literature review<sup>2</sup>. Of these cases, nine were caused by suppurative parotitis and seven cases by parotid abscess<sup>3</sup>.

### CASE REPORT

A forty years old Malay lady of no medical illness presented with left sided neck swelling for two weeks. She had sought medical treatment but despite antibiotics, the swelling did not subside. Her presenting symptoms were intermittent fever, reduced oral intake and jaw pain during mouth opening. There was no dysphagia, sore throat, dental pain, history of pain on mastication or parotid disease. On examination, she was comfortable and afebrile. She had trismus with left sided neck swelling measuring about 5 x 6cm involving the angle of mandible, which was indurated and inflamed but no area of fluctuancy. The facial nerve function was normal. No cervical lymphadenopathy were palpable. Per oral examination was unremarkable. The white blood cell count was  $13.6 \times 10^9/l$ , the fasting glucose level was 10.9 mmol/L. She was treated with intravenous antibiotics (IV Augmentin 1.2gm tds and IV Metronidazole 500mg tds). In the ward it was noted that her glucose and blood pressure readings were persistently high. Hence insulin injection and antihypertensive drug were started. The following day she developed left peripheral facial palsy (House-Brackmann grade IV). Pustules were noted on the swelling. An urgent CT neck was done revealing left parotid abscess involving the deep lobe (Fig. 2). Incision and drainage of the abscess under general anaesthesia was immediately done draining frank

pus. Culture of the purulent material failed to yield any bacterial, fungal or acid-fast bacilli organisms. Histopathology examination showed no evidence of malignancy. Postoperatively she remained afebrile, and her diabetes was controlled. She was discharged home well after one week with oral hypoglycaemic agent, antihypertensive drug and daily dressing of neck wound. After two month, her facial nerve dysfunction improved to House-Brackmann grade III. The neck wound healed completely and there was no residual enlargement of the parotid gland. Her facial asymmetry improved to House-Brackmann grade II at 3 month review post surgery. At six month review, her facial nerve has fully recovered.

### DISCUSSION

Parotitis can be caused by a variety of pathogens. The most common bacteria are *Staphylococcus aureus*, *Streptococcus pyogenes*, *Mycobacterium tuberculosis*, anaerobes and *Pseudomonas* spp. Viral agents such as Epstein-Barr virus, HIV and human parvovirus B19 have been reported to cause intraparotid lymphadenitis with facial palsy. *Candida albican* has also been isolated in a parotid abscess<sup>2</sup>. In most of the reported cases of parotitis with facial palsy, no pathogen was isolated<sup>4</sup>. Similarly in this case, cultures were negative. Diabetes mellitus was an aggravating factor as it was previously undiagnosed. When poorly controlled, there is disturbance of cell-mediated immunity, alterations in opsonization and decreased chemotactic activity of granulocytes and monocytes.

A few mechanisms have been proposed of the pathogenesis of facial nerve dysfunction secondary to inflammatory parotid gland disease. These include the virulence of the offending organisms and perineuritis. In this case it may be possible it arises from local toxic effects from the intense surrounding parotitis, and ischaemic neuropathy with acute facial nerve compression secondary to the rapidly expanding abscess.

The House-Brackmann grading system is a useful tool in assessing the degree of facial weakness in facial nerve injury. Grade I is normal, Grade II is mild dysfunction, complete eye closure with minimal effort. Grade III shows obvious weakness, but eye closure is complete and asymmetrical mouth movement with maximal effort. Grade IV shows disfiguring weakness with inability to lift eyebrow, incomplete eye closure and asymmetry of mouth. Grade V shows barely perceptible motion, slight movement of corner of mouth. Grade VI is total paralysis with loss of tone.

This article was accepted: 23 March 2009

Corresponding Author: Noorizan binti Yahya, Department of Otorhinolaryngology, Head and Neck Surgery, University Kebangsaan Malaysia Medical Centre, Bandar Tun Razak 56000 Cheras, Kuala Lumpur Email: noorizan\_yahya@yahoo.com

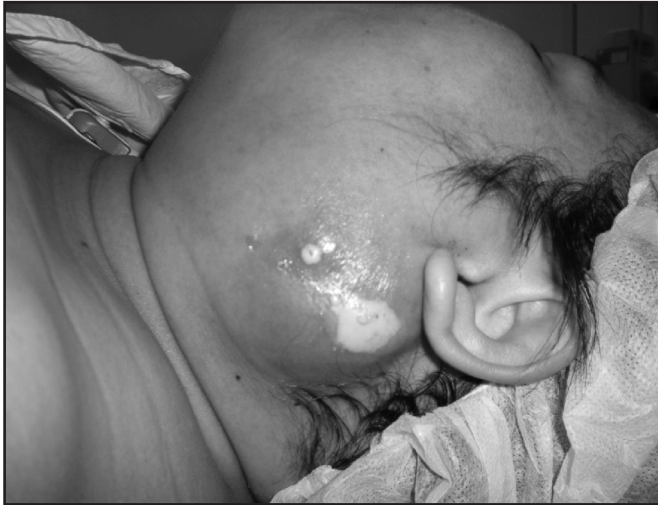

Fig. 1: Picture showing left parotid abscess.

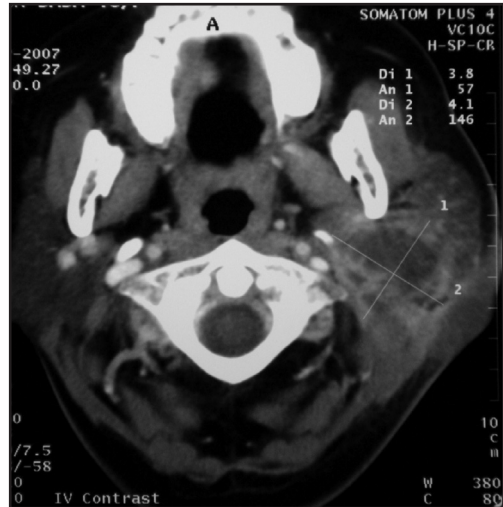


Fig. 2: CT neck showing left parotid abscess involving the deep lobe.

As a general therapeutic approach to bacterial parotitis, broad-spectrum intravenous antibiotics which cover gram-positive and gram-negative bacteria and anaerobes were started. Hydration, oral hygiene and sialogogues should be emphasized. A CT scan is necessary to rule out underlying malignancy especially when facial nerve paralysis occur. It also helps to differentiate between abscess and parotitis as well as indicating the precise location of the collecting purulent material. Surgical intervention is required once abscess is confirmed, taking care not to further damage the nerve. In this case, prompt surgery was performed in an attempt to restore a good recovery of facial nerve function.

The degree of facial nerve recovery does not correlate with the severity or the extent of the initial nerve involvement, or presence of infection. However it depends on the amount of

trauma to the nerve during surgery<sup>1</sup>. The chances of complete recovery is good as reported in all cases of parotid abscess except one case<sup>5</sup>. In our patient, her facial nerve function was fully recovered after six months.

#### REFERENCES

1. De Lozier HL, Spinella MJ, Johnson GD. Facial nerve paralysis with benign parotid mass. *Ann Otol Rhinol Laryngol* 1989; 98: 644-7.
2. Marioni G, Rinaldi R, de Filippis C, Gaio E, Stafieri A. Candidal abscess of the parotid gland associated with facial nerve paralysis. *Acta Otolaryngol* 2003; 123: 661-63.
3. Smith DR, Hartig GK. Complete facial paralysis as a result of parotid abscess. *Otolaryngol Head Neck Surg* 1997; 117: S114-7.
4. Andrews JC, Abemayor E, Alessi DM, Canalis RF. Parotitis and facial nerve dysfunction. *Arch Otolaryngol Head Neck Surg* 1989; 115: 240-2.
5. Shone GR, Steward S. Facial paralysis in parotitis. *Br J Surg* 1985; 72: 902.