

# CASE REPORT

## Penetrating Ocular Injury by Durian Fruit

S Aziz, MS, T Asokumaran, MMed, G Intan, MS

Department of Ophthalmology, Sarawak General Hospital, 93586 Kuching, Sarawak, Malaysia

### SUMMARY

Durian may inflict severe body injury when it drops from the tree. This case report describes a patient who presented with facial and penetrating eye injury when a ripe durian fruit dropped onto her face while harvesting the fruits under the tree. The authors emphasized the importance of facial and eye protective devices during durian fruit harvesting season.

### KEY WORDS:

*Durian, Eye, Penetrating injury*

### INTRODUCTION

The durian (scientific name = *Durio zibethinus*) is a large seasonal crop in the South East Asia. It is less known outside this region due to numerous problems relating to shipping and shelf life. Although the smell is pungent and intolerable to certain people, it is regarded as a delicacy by many throughout Asia due to its taste. The trees are abundant in the remote areas where facial or eye protection from the durian spines are largely unknown by the population.

### MATERIALS AND METHODS

Interventional case report.

### RESULTS

A 40-year old woman was referred for facial injury after being hit by a durian fruit. She was collecting the ripe durian fruits under the trees when, without any warning, a durian fruit dropped from the tree and hit her face. At the time of injury, she did not wear any head or ocular protection devices.

At presentation, there was a deep right upper lid laceration. The right side of the face was marked by durian spikes. Visual acuity in the right eye was perception to light (PL). The eye examination revealed extensive corneal laceration with corresponding iris prolapse at the temporal quadrant. There was possibly earlier extrusion of the lens and other ocular contents in view of the collapsed eyeball. The cornea was hazy and the anterior chamber (AC) details were poor due to full hyphema. There was no view of the posterior segment.

A right eye corneal suturing and AC washout were performed under general anesthesia. The lid laceration was also sutured. Post-operatively, her visual acuity remained perception to light (PL). There was presence of a relative afferent pupillary defect (RAPD). Despite the AC washout, there was still hyphema present. The cornea was hazy with full hyphema.

(Figure 1) A/B scan ultrasonography revealed extensive vitreous hemorrhage and the status of the retina could not be determined.

During follow up one month later, the lid laceration healed well. However, the eye became phthysical with no remaining useful vision. Four months after the initial injury, ocular prosthesis fitting was done for cosmetic reason. The patient was counselled regarding the injury and prevention of further ocular injury. She was also advised to wear eye goggles while harvesting fruits during the subsequent durian cropping season.

### DISCUSSION

Durian trees grow in hilly areas largely in the remote areas of the South East Asia. They usually grow to an average height of twelve meters. When mature, the trees can bear 400 to 500 fruits, and take about four months from flowering to the fruit drop<sup>1</sup>. The mode of cropping is by harvesting the ripe fruit which has dropped on the ground.

The fruit usually weighs 0.2 to 1.5kg. It is ovoid to ellipsoid in shape with or without lobes, and covered with short, soft and pentagonal spines.<sup>1</sup> (Figure 2) When opened, it reveals yellow flesh with pungent smell.

Due to the tree height, the weight of the fruit and the spines, it may inflict injury when it accidentally dropped onto the person who harvests the fruits under the trees. Although this mainly results in body or head injury, it may also cause penetrating ocular injury when the person is looking up the tree while harvesting<sup>2</sup>. There are no published figures or case reports in the literature regarding eye injury due to durian fruit possibly due to underreporting.

Head or ocular protection devices are not widely used during fruit cropping season. This is largely due to the devices being not readily available in the remote areas where most of the durian farms are located. Proper devices may also not be accessible due to poverty. On the other hand, many farmers are ignorant about eye safety due to lack of awareness and poor educational background<sup>1</sup>.

Treatment of ocular trauma depends on the patient's general condition and the location, extent and severity of the injury<sup>2,3</sup>. Significant factors at presentation which may predict a poor visual outcome include wound length greater than 10mm, presence of RAPD, presence of lid laceration and an initial visual acuity worse than 6/60<sup>4,5</sup>. In this patient, the

*This article was accepted: 6 June 2009*

*Corresponding Author: Mohamad Aziz Salowi, Department of Ophthalmology, Sarawak General Hospital, 93586, Kuching, Sarawak, Malaysia  
Email: tedmy@yahoo.com*

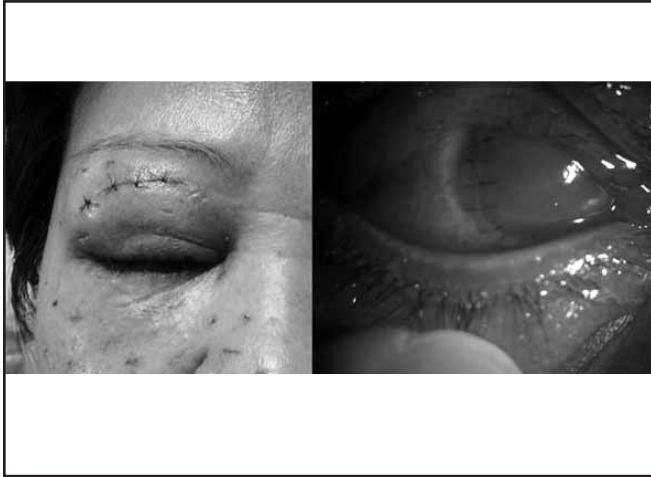


Fig. 1: After surgical repair; Marks of durian spines can be seen on the patient's face. The cornea appeared hazy with no view of the iris and the posterior segment due to hyphema.

Note: Author has obtained consent from patient for this publication.




Fig. 2: The durian fruit with its spines

lid and the eyeball were repaired in a timely manner. However, due to the severity of the injury at presentation, the poor surgical and visual outcome were as anticipated.

Prevention is the best means of eliminating mortality and minimizing the morbidity of injury due to durian fruit. Public education by media or school can be carried out especially in the remote areas where the durian provides an income for the population. Although it may appear peculiar to the local residents, safety helmets and goggles still remain the finest method of protection from the dropping durian fruits during harvesting season.

REFERENCES

1. Asmah S, Yazid B. Durian Nyekak. In: Agriculture Department of Sarawak Leaflet, First Edition. Miri: Stesen Pertanian Kabuloh, 2007.
2. Rubsamen PE. Posterior Segment Ocular Trauma. In: Yanoff M, Duker JS, editors. Ophthalmology. Second ed. St. Louise: Mosby, 2004; 140: 1007-12.
3. Kuhn F, Morris R, Witherspoon CD. A standardized classification of ocular trauma. Ophthalmology 1996; 103: 240-3.
4. Esmaeli B, Elner SG, Schork MA, Elner VM. Visual outcome and ocular survival after penetrating trauma. A clinicopathologic study. Ophthalmology 1995; 102(3): 393-400.
5. Rahman I, Maino A, Devadason D, Leatherbarrow B. Open globe injuries: factors predictive of poor outcome. Eye 2006; 20(12): 1336-41.