

The Association of Concha Bullosa and Deviated Nasal Septum with Chronic Rhinosinusitis in Functional Endoscopic Sinus Surgery Patients

T E S Vincent, M S ORL-HNS (UKM); B S Gendeh, M S ORL-HNS (UKM)

Department of Otorhinolaryngology, Head & Neck Surgery, Faculty of Medicine, Hospital Universiti Kebangsaan Malaysia (HUKM), Jalan Yaacob Latif, 56000 Cheras, Kuala Lumpur, Malaysia

SUMMARY

Chronic rhinosinusitis (CRS) remains a prevalent disease and a major cause of morbidity for many patients and functional endoscopic sinus surgery (FESS) is the gold standard for the treatment of CRS. Many factors contribute to the development of CRS, among others nasal anatomic variation. The authors aim to study the association of concha bullosa and deviated nasal septum with CRS patients requiring FESS amongst the diversified multiethnic Malaysian race. The records of 137 patients with CRS who had undergone FESS between March 2002 and October 2006 at the Department of Otorhinolaryngology, Head and Neck Surgery of the Hospital Universiti Kebangsaan Malaysia (HUKM), Kuala Lumpur were retrospectively reviewed. The data revealed that deviated nasal septum (DNS) and concha bullosa (CB) were the two commonest anatomical variations in the nasal cavity. In this study, CB was statistically significant amongst the females and in the Chinese and Indian ethnic groups. DNS is also prevalent but has no significant statistical relationship with sex, age, ethnic group in the local context. CB and DNS are coincidental variations and this study disprove that DNS is associated with CB in its development and pathogenesis of CRS. The mere presence of both these conditions also does not predispose the patients to CRS in the adjacent paranasal sinuses.

KEY WORDS:

Chronic rhinosinusitis, concha bullosa, deviated nasal septum, anatomic variation, functional endoscopic sinus surgery, ethnicity

INTRODUCTION

Functional endoscopic sinus surgery (FESS) has gained widespread acceptance among otorhinolaryngologists as the gold standard for the treatment in chronic rhinosinusitis (CRS). The success of FESS is very much dependant on the surgeon's understanding and interpretation of the functional anatomy of the nasal cavity, paranasal sinuses and their drainage pathways. At the focus of interest is the ostiomeatal complex (OMC) in the lateral wall of the nose which is thought to be the key in the pathogenesis of CRS. Local anatomic variations including concha bullosa, deviated nasal septum (DNS), Haller cells, paradoxical middle turbinates, agger nasi cells and many others may be the source

of middle meatal obstruction and subsequent rhinosinusitis. Excluding agger nasi cells which was present in almost all sampled patients in one study¹, the most common anatomical variations are concha bullosa (CB) and DNS.

Defined as pneumatization of the middle nasal concha², CB is believed to represent an extension of ethmoid air cell development, rather than a consequence of any prior pathological process^{1,3}. It may be present unilaterally or bilaterally, be very small or may attain a considerable size. CB is best diagnosed radiographically as they are easily identified on CT scan, appearing as an air space of the middle turbinate surrounded by an oval bony rim (Figure 1). The frequency of the CB itself showed a wide range of variation, reported in the literature as 15%⁴, 30%⁵, 50%⁶ and even 80%⁷. It is hypothesized that the enlarged concha may compress or deviate the uncinate process against the lateral wall of the nasal cavity or compress the middle meatus and narrow the ethmoidal infundibulum, therefore causing ipsilateral maxillary sinus disease. From literature review, some studies suggest significant correlation between CB and sinus disease⁸, while others found little or no significance^{2,3,6,9}.

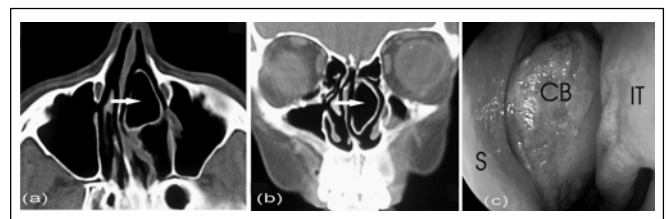


Fig. 1: (a) Axial and (b) coronal CT images of a left concha bullosa (white arrow) (c) nasal endoscopic view of the same concha bullosa. S: nasal septum, CB: concha bullosa, IT: left inferior turbinate.

DNS refers to the asymmetric bowing of the nasal septum which is commonly associated with septal bony spurs. Some can push the middle turbinate laterally, narrowing the middle meatus and therefore resulting in obstructed drainage of the ipsilateral maxillary, anterior ethmoid, and frontal sinuses. It was hypothesized that the septal deformity provides a large space for the middle turbinate to expand, making blockage to the ipsilateral

This article was accepted: 29 June 2010

Corresponding Author: Dr Vincent Tan Eng Soon, Department of Otorhinolaryngology-Head & Neck Surgery, Faculty of Medicine, Hospital Universiti Kebangsaan Malaysia (HUKM), Jalan Yaacob Latif, 56000 Cheras, Kuala Lumpur, Malaysia Email: drvincenttan@gmail.com

middle meatus less likely, instead contributes to contralateral sinus disease due to narrowing of the opposite OMC. While some researchers⁶ disputes this hypothesis, others¹ reported a higher incidence of DNS in CRS patients and it was significantly associated with OMC disease. Also, there seems to be an apparent relationship between CB with DNS¹⁰ even though some investigators¹ disagreed. Therefore, this study will also focus and elaborate on possible association between CB and DNS with CRS in the multiethnic Malaysian race.

MATERIAL AND METHODS

This is a retrospective study of all patients who underwent FESS in the Department of Otorhinolaryngology, Head and Neck Surgery (ORL-HNS) at Hospital Universiti Kebangsaan Malaysia (HUKM), Kuala Lumpur. The study included all consecutive patients with chronic rhinosinusitis who had undergone FESS at the Department of ORL-HNS at our hospital. The list of patients was obtained from the OT list between March 2002 and October 2006. Based on the name or registration number, the patient’s file including the CT scan was traced from the Record Office or the clinic. All included patients should also have retrievable preoperative high resolution 2 or 3mm-slice coronal view CT scan of the paranasal sinuses. Patients will be excluded if the CT scans were not available or if they had congenital deformities, previous surgery, trauma, and malignancy involving the nose, paranasal sinuses or maxillofacial region. Patients with CRS arising from invasive fungal rhinosinusitis or dental pathologies, e.g. unresolved periapical abscess, were also excluded.

Radiologically, any degree of pneumatization of the middle turbinate is considered significant CB. DNS is considered significant if the septal spur was facing the middle meatus or if the septal deviation narrowed ipsilateral nasal airway. In S-shaped DNS, the most markedly deviated site is selected. The incidence of each nasal deformity on the side ipsilateral to the diseased maxillary sinus according to the different race and sex was noted. It was then compared to the incidence of the abnormality on the side with normal maxillary sinus. Unless otherwise mentioned, chi-square test was performed for most of the statistical analysis. For analysis of predominant side of CRS symptoms in relation to CB and DNS (as in Tables III to V), each half-head was considered as a separate anatomical and physiological entity⁶. In an effort to provide the truest possible comparison, by this method, the two sides of the paranasal sinuses are compared against each other, therefore eliminating other intrinsic contributory factors to CRS (eg. allergy, idiosyncracies of therapy etc). Any difference in severity of disease as judged clinically or radiologically in a particular individual can be considered to be due to possible anatomical variation. Predominant side of symptoms is taken from patient’s history, or obvious opacity in the paranasal sinuses or side of surgery performed, in decreasing order of priority.

RESULTS

During study period from March 2002 and October 2006, 168 patients had undergone FESS for the first time at the Department of ORL-HNS, HUKM. Of these, the file or paranasal CT scan of 31 patients (18.4 per cent) was incomplete or could not be located for various reasons, therefore the available number of subjects included in this

retrospective review was 137. The patients totaled 137 and constituted a statistically normal population of study (Kolmogorov-Smirnov test, p=0.062). The ages ranged from 11 to 68 years with a mean age of 37.4 ± 14.9 years. There were 74 (54.0%) male patients and 63 (46.0%) female patients, with a male to female sex ratio of 1.17. The commonest age range was 40-49 (24.8%) years. The main racial groups in Malaysia are Malay, Chinese and Indian. The racial composition in this study was Malay (48.1%), Chinese (31.4%), Indian (18.2%). There were incidentally 3 patients (2.2%) of Middle Eastern and Bangladeshi origin.

Concha Bullosa (CB)

The prevalence rate was 35/137 (25.5%). Unilateral CB was commoner (22/35, 62.9%) than bilateral CB (13/35, 37.1%). Seven (20%) had right CB only, 15 (42.9%) had left CB only and bilateral CB was found in 13 (37.1%) patients. The association of CB with sex was statistically significant (p<0.05), as shown in Table I.

The age of the CB patients ranged from 11 to 68 years old, with the commonest age group being 40-49 years (11/35, 31.4%). The mean age was 39.7 years and the mean age of patients with CB was not significantly different from patients without CB (student t-test, p>0.05). CB was most prevalent among the Malays (18/35, 51.4%), least among the Chinese (14.3%), as shown by Table II. CB was statistically associated with the Chinese (p= 0.012) and Indian (p= 0.019) ethnic groups but not the Malay ethnic group (p= 0.655).

Table I: Distribution of CB with gender of the patients

	CB		Total
	Present	Absent	
Male	13	61	74
Female	22	41	63
Total	35	102	137

Table II: Distribution of CB with ethnicity

	CB		Total
	Present	Absent	
Malay	18	48	66
Chinese	5	38	43
Indian	11	14	25
Others	1	2	3
Total	35	102	137

The presence of ipsilateral CB was not statistically significant to be associated with an increased incidence of ipsilateral CRS (p=0.715), as shown in Table III. Of those patients with CB, 60% of them have coexisting DNS. However, patients with CB have no statistically significant association with an increased incidence of DNS as compared to non-CB patients. CB was not statistically more likely to cause DNS to the contralateral side (p=0.676), as illustrated in Table IV.

There was also no statistical relationship between unilateral or bilateral CB with DNS (Fisher’s exact test, p=0.488). The predominant symptom of CB patients was nasal obstruction 31/35 (88.6%), however it was not statistically increased as compared to patients without CB (p>0.05).

Table III:
Presence of CRS symptoms with ipsilateral or contralateral CB

		Presence of CRS symptoms		Total
		Ipsilateral	Contralateral	
Ipsilateral CB	Present	34	14	48
	Absent	154	72	226
Total		188	86	274

* Assumption: each side of the paranasal sinus is taken as a single unit, therefore the total number of sinuses are 137 x 2 = 274

Table IV: Association of ipsilateral CB with ipsilateral or contralateral DNS

		DNS		Total
		Ipsilateral	Contralateral	
Ipsilateral CB	Present	14	16	30
	Absent	50	48	98
Total		64	64	128

* Assumption: each side of the CB and deviated nasal septum are taken as a single unit.

Table V: Presence of CRS Symptoms with Ipsilateral or Contralateral DNS

		Presence of CRS symptoms		Total
		Ipsilateral	Contralateral	
Ipsilateral DNS	Present	28	13	41
	Absent	78	63	141
Total		106	76	182

DNS

Of the 137 patients, 64 (46.7%) have DNS of various degree with 43 patients without coexistent CB. Thirty- one patients had DNS to the right and 33 to the left. There were 34 male (54.7%) and 29 female (45.3%) patients, with a male to female sex ratio of 1.21. However, there was no significant association between DNS and sex of the patients (p >0.05). The range of age at presentation was between 12 to 66 years, with a mean age of 34.1 years. The commonest age groups are both the 20-29 and 30-39 groups. However, the mean age between patients with or without DNS was not significantly different (student t-test, p>0.05). There was no statistical association between DNS and all ethnic groups (p> 0.05 for all groups).

In those DNS patients without CB, the commonest symptom was nasal obstruction (90.1%). Patients with DNS had a higher mean score for facial pain but lower mean score for rhinorrhea and nasal obstruction as compared to non-DNS patients but however, it was not statistically significant for all 3 categories (p> 0.05 for all groups). The presence of ipsilateral DNS in the absence of other known anatomical variation also did not significantly contribute to increased symptoms of ipsilateral CRS, as illustrated in Table V (p=0.138)

DISCUSSION

The order of frequency of the different racial groups does mirror that of the general Malaysian population even though the ratios differ slightly. There is almost equal number of male and female CRS patients, with slight male gender predilection. However, literature review shows a slight female preponderance for CRS. Female to male ratio was reported as between 55-60% versus 40-45%^{3,6,8}, even though no specific cause was elaborated.

The prevalence rate of CB in this study is 25.5%. A wide range of prevalence has been reported in the literature perhaps due to different criteria of diagnosis and sensitivity of analysis. CB occurs in all age group, most probably reflecting its embryological origin of the ethmoidal air cell development. Its manifestation at different ages later is probably the cumulative effects of other influences, for instance environment, allergy, trauma etc. CB is best diagnosed radiographically as they are easily identified on CT scan, appearing as an air space of the middle turbinate surrounded by an oval bony rim. The mean age at presentation of CRS is 39.7 years, consistent with other studies^{2,7,8}. CB is commoner in females in our analysis and this is statistically significant. However, literature review reveals no obvious cause. Unilateral CB is indeed commoner than bilateral^{2,6}, as indicated likewise in this study.

The presence of CB did not statistically contribute to an overall increased incidence of ipsilateral CRS. The etiological role of CB in CRS has been controversial. Our finding concurred with some studies^{2,6,10,12}, although others⁵ reported otherwise. Several reasons could be considered. Firstly, the CB was included regardless of its size. In this study, CB is defined as any degree of aeration of the middle turbinate, whether unilateral or bilateral. While there is no doubt that large CB impinging directly on the OMC can predispose to maxillary sinus ostium obstruction and subsequently CRS, many others could be small and physiologically insignificant. In fact, Yousem DM remarked “it appears that the size, not the presence of these normal variations is the critical factor”¹². Secondly, all patients are symptomatic and had demonstrated significant endoscopic findings that required preoperative CT scan. Therefore this does not necessarily reflect the natural progression of history of a CB to the genesis of the OMC disease. Thirdly, there may be possible difference in the genetic tendency towards CB formation. In this study, CB was statistically associated with the Chinese and Indian ethnic group.

Stammberger¹³ proposed 2 hypothesis to the development of CB. Firstly, DNS provides a large contralateral concave nasal space (“e vacuo”) for the expansion of the middle turbinate therefore resulting in CB formation. Alternatively, both CB and DNS are two incidental coexisting pathologies. This study disproves the “e vacuo” hypotheses as CB was not statistically more likely to cause DNS to the contralateral side and there is no statistical relationship between unilateral or bilateral CB with DNS. On the other hand, Aktas D *et al*¹⁰ found a statistically significant relationship between DNS and unilateral but not bilateral CB.

DNS is the commonest normal anatomical variant detected with a prevalence rate of DNS at 50%³, closely mirroring the 46.7%t in this study. There is no standard definition of DNS, but it usually refers to convexities of the septum to

one side with accompanying deformities of midline structures. In this study, patients with DNS have a higher mean score for facial pain but lower mean score for rhinorrhea and nasal obstruction as compared to non-DNS patients. In contrast, a study by Bhattacharyya showed non-CRS patients with only DNS reported higher mean nasal obstruction scores but lower rhinorrhea symptom severity scores than the non-DNS CRS patients¹⁴. This is possibly because of facial pain secondary to the septal deviation (ie, Sluder's syndrome or "contact point" headaches). Also, nasal obstruction can be influenced by a variety of other factors, eg. temperature changes and may occur despite the absence of any significant DNS. The site of DNS itself (which was not taken into consideration in this study) may also be a contributory factor in nasal obstruction. Cole *et al* showed that in the bony cavum, deviations that appear to be obstructive on physical examination led to only a minimal increase in nasal resistance. Resistance was generally greater with more inferior deviations¹⁵.

This study also showed no significant association between the rate of ipsilateral and contralateral side of CRS in relation to the the presence of ipsilateral or contralateral DNS. Some researchers¹⁶ also found no statistically significant difference between DNS group and non-DNS group with respect to the CRS, having excluded the subjects with ostiomeatal anatomic variations that has differentiated this study from the previously reported researches (isolated DNS). The rates of CRS ipsilateral to and contralateral to the side of the DNS were not statistically different among CRS groups.

There are however limitations to this study. In the presence of gross polyposis, the usual anatomical landmarks are not well visualized, and pneumatized air spaces can be filled with soft tissue density. Therefore, certain anatomical variations can be inadvertently missed. As this study is a retrospective review, therefore the history of the patients was dependant on available documentation, subject to bias by previous assessor. It is also recommended that the acoustic rhinomanometry be used in institutions to objectively document nasal obstruction, a very subjective symptoms, in future prospective studies.

CONCLUSION

Excluding agger nasi cells, DNS and CB are the two commonest anatomical variations in the nasal cavity. In this study, CB was statistically more common among females and statistically associated with the Chinese and Indian

ethnic groups. DNS is also prevalent but has no significant statistical relationship with sex, age, ethnic group in the local context. CB and DNS are coincidental variations and this study disprove that DNS is associated with CB in its development and pathogenesis of CRS. The mere presence of these conditions also does not predispose the patients to CRS in the adjacent paranasal sinuses.

ACKNOWLEDGEMENT

The authors would like to express their gratitude for the invaluable expertise in statistical analysis by Dr. Mohd Nizam Jemoim from the Public Health Department.

REFERENCES

1. Bolger WE, Butzin CA, Parsons D.S. Paranasal sinus bony anatomic variations and mucosal abnormalities: CT analysis for endoscopic sinus surgery. *Laryngoscope* 1991;101:56-64.
2. Zinreich SJ, Mattow DE, Kennedy DW, Chisholm HL, Diffley DM, Rosenbaum AE. Concha bullosa: CT evaluation. *J Comput Assist Tomogr* 1988;12:778-84.
3. Lam WW, Liang EY, Woo JK, van Hasselt A, Metreweli C. The etiological role of concha bullosa in chronic sinusitis. *Eur Radiol* 1996;6:550-2.
4. Wolf JS, Biedlingmaier JF. The middle turbinate in endoscopic sinus surgery. *Curr Opin Otolaryngol Head Neck Surg* 2001;9:23-6.
5. Arslan H, Aydinoglu A, Bozkurt M *et al*. Anatomic variations of the paranasal sinuses: CT examination for endoscopic sinus surgery. *Auris Nasus Larynx* 1999;26:39-48.
6. Nadas S, Duvoisin B, Landry M, Schnyder P. Concha bullosa: frequency and appearances on CT and correlations with sinus disease in 308 patients with chronic sinusitis. *Neuroradiol* 1995;37:234-7.
7. Sarna A, Hayman LA, Laine FJ, Taber KH. Coronal imaging of the osteomeatal unit: anatomy of 24 variants. *J Comput Assist Tomogr* 2002;26:153-7.
8. Lloyd GA. CT of the paranasal sinuses: study of a control series in relation to endoscopic sinus surgery. *J Laryngol Otol* 1990;104:477-81.
9. Kieff DA, Busaba NY. Isolated chronic maxillary sinusitis of non-dental origin does not correlate per se with ipsilateral intranasal structural abnormalities. *Ann Otol Rhinol Laryngol* 2004;113:474-6.
10. Aktas D, Kalcioğlu MT, Kutlu R, Ozturan O, Oncel S. The relationship between the concha bullosa, nasal septal deviation and sinusitis. *Rhinol* 2003;41:103-6.
11. Busaba NY, Kieff D. Endoscopic sinus surgery for inflammatory maxillary sinus disease. *Laryngoscope* 2002;112:1378-83.
12. Yousem DM. Imaging of the sinonasal inflammatory disease. *Radiol* 1993;188:303-4.
13. Stammberger H. In: *Functional endoscopic sinus surgery, the Messerklinger technique*. Philadelphia: B.C. Decker. 1991:156-68.
14. Bhattacharyya N. Symptom and Disease Severity Differences Between Nasal Septal Deviation and Chronic Rhinosinusitis. *Otolaryngol Head Neck Surg* 2005;133: 173-7.
15. Cole P, Chaban R., Naito K., Oprysk D. The obstructive nasal septum. *Arch Otolaryngol Head Neck Surg* 1988;114:410-2.
16. Yasan H, Dogru H, Baykal B, Döner F, Tüz M. What is the Relationship Between Chronic Sinus Disease and Isolated Nasal Septal Deviation? *Otolaryngol Head Neck Surg* 2005;133:190-3.