

# Papillary Thyroid Carcinoma Presenting with Intraluminal Tracheal Mass Symptoms

Irfan Mohamad, MD, MMed (ORL-HNS)\*, Ali Haron, MD, MMed (ORL-HNS)\*\*

\*Department of Otorhinolaryngology-Head & Neck Surgery, School of Medical Sciences, Universiti Sains Malaysia Health Campus, 16150 Kota Bharu, Kelantan, Malaysia, \*\*Department of Otorhinolaryngology, Hospital Raja Perempuan Zainab II, 15586 Kota Bharu, Kelantan, Malaysia

### SUMMARY

Papillary thyroid carcinoma is a common thyroid malignancy reported world wide. It affects females more commonly in the 4th to 6th decades of life. The patients usually present with a painless anterior neck mass and occasionally with lymph node involvement. We report a case of an elderly male who presented with hoarseness and hemoptysis, which warranted bronchoscopy. Biopsy of the intraluminal tracheal mass revealed the diagnosis of papillary thyroid carcinoma. Computed tomography scan of the neck confirmed the presence of the primary lesion in the right thyroid lobe with invasion into the adjacent trachea and esophagus.

### KEY WORDS:

*Thyroid, adenocarcinoma, papillary, invasion, trachea, lumen*

### INTRODUCTION

A thyroid tumor usually presents as a slow growing painless anterior neck mass. The readily appreciated presence of the mass in the neck usually makes the patient present early for medical attention. Not uncommonly, lymph node metastasis can be the sole presentation. But more commonly it occurs together with the thyroid mass. Without these symptoms, thyroid pathology is usually not suspected.

### CASE SUMMARY

MNM, a 71-year-old Malay male, an ex-smoker, presented with hoarseness associated with loss of weight and loss of appetite for 2 months duration. It was recently complicated with dysphagia. He also admitted having on and off hemoptysis. He however denied any contact with tuberculosis patients.

Clinical examination revealed no external abnormality. There was no neck mass and other cervical lymphadenopathy. A 70 degree laryngoscopy showed uncompensated right vocal cord palsy. Bronchoscopy was commenced. There was presence of a lobulated mass located at the right lateral wall of the trachea (Figure 1). Further down, endoscopy beyond the carina revealed no abnormality in both main bronchi. Biopsy taken from the tracheal mass was consistent with adenocarcinoma, papillary type most likely from thyroid or lung.

A computed tomography scan of the neck and thorax was obtained. It revealed the right thyroid lobe mass measuring 2.9 cm x 2.7 cm x 4.3 cm with infiltration into right side of trachea causing narrowing of the lumen. Posteriorly, there was no plane of demarcation with the right anterolateral wall of esophagus. There was obliteration of tracheo-esophageal groove which suggested local infiltration. Shotty nodes were picked up in the anterior cervical bilaterally, pretrachea and subcarina groups.

The patient was referred to for radiotherapy in view of locally advanced tumor. However after he underwent whole body scan, he default subsequent follow up. A phone call that was made to the relatives confirmed that the patient had succumbed to his illness 3 months after the due follow up date.

### DISCUSSION

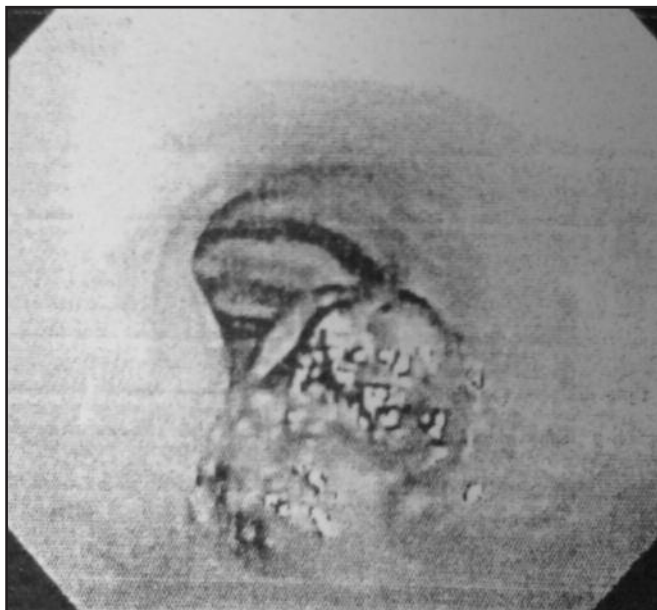
Papillary thyroid carcinoma (PTC) is the commonest form of thyroid malignancy, which accounts for 88% of for all thyroid tumors in United States. It is followed by follicular (9%) and poorly-differentiated (3%) tumor<sup>1</sup>. A similar pattern was seen in Malaysia. In a retrospective report of an 11-year study in Hospital Universiti Sains Malaysia, the frequency of PTC detected was 76.6% among all thyroid malignancies operated<sup>2</sup>. The female to male ratio seen was 5.7:1 in three states in Malaysia. The age with highest frequency was between 30-40 years old<sup>3</sup>.

PTC carries a good prognosis. Common presentations include a painless anterior neck mass with normal overlying skin. PTC presented as a fungating mass on the skin has been reported; however in that case it was a recurrent tumor after primary surgery and radio iodine ablation had been done<sup>4</sup>. PTC presenting with airway symptoms with normal external neck appearance, to our best knowledge is never reported.

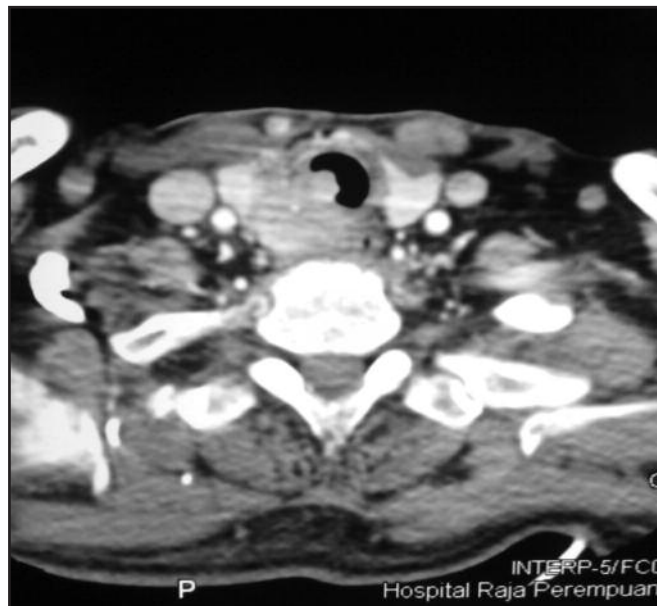
In the index case, the patient underwent laryngoscopy as part of the assessment of the hoarseness. It was found that the right vocal cord was immobile. Vocal cord palsy by itself should warrant a neck computed tomography (CT) scan if other local factors were ruled out, and subclinical asymptomatic thyroid malignancy is one of them. In addition, this patient also complained of hemoptysis which warranted a bronchoscopy and a CT. The result of CT neck in this case explained the primary problem for both the unilateral vocal palsy and hemoptysis.

*This article was accepted: 18 October 2012*

*Corresponding Author: Irfan Mohamad, Department of Otorhinolaryngology-Head & Neck Surgery, School of Medical Sciences, Universiti Sains Malaysia Health Campus, 16150 Kota Bharu, Kelantan, Malaysia Email: irfan@kb.usm.my*



**Fig. 1 :** Intratracheal mass appeared lobulated and occupied 50% of the lumen.



**Fig. 2 :** Axial CT scan of the neck showed the right thyroid lobe tumor invaded the trachea going intraluminally. Note the mass did not enlarged anteriorly.

Direct invasion of the tumor to the tracheal wall can easily affect the recurrent laryngeal nerve which resides in the tracheo-esophageal groove. Further deeper extension into the lumen will produce space-occupying lesion effect in the airway which includes shortness of breath or noisy breathing. Ulceration of the tumor either by high pressure cough reflex, or even the vascularity of a tumor itself will readily produce hemoptysis.

A large thyroid mass produces dysphagia, however a relatively small lesion with local invasion can fix the tracheal and the esophagus causing swallowing disturbance besides the mass effect produced by the posteriorly enlarged mass. Metastatic disease of PTC often goes to cervical lymph nodes. Apart from neck node deposits, it occasionally spread to lung and bones. A case of asymptomatic PTC presented with leg pain and foot drop was reported. It was later proven as metastatic PTC to the hip bone<sup>5</sup>.

The treatment for an operable PTC is surgery followed by radio iodine ablation. In this particular case, the lesion was staged as T4a (moderately advanced disease) and the surgery if to be commenced must be together with tracheal resection and end-to-end anastomosis. In view of the tumor stage and the patient age and co-morbidities, he was resorted to oncological palliative treatment. If the PTC with tracheal invasion is limited with no progress to involve the mucosal surface, tracheal shaving can be recommended.

#### REFERENCES

1. Davies L, Welch HG. Increasing incidence of thyroid cancer in the United States, 1973–2002. *JAMA* 2006; 295(18): 2164-7.
2. Othman NH, Omar E, Naing NN. Spectrum of Thyroid Lesions in Hospital Universiti Sains Malaysia Over 11-Years and A Review of Thyroid Cancers in Malaysia. *Asian Pac J Cancer Prev* 2009; 10(1): 87-90.
3. Htwe TT. Thyroid malignancy among goitrous thyroid lesions: a review of hospital-based studies in Malaysia and Myanmar. *Singapore Med J* 2012; 53(3): 159-63.
4. Irfan M, Baharudin A, Ananda Dorai A. An Unusual Presentation of a Thyroid Malignancy: A Case Report. *The International Medical Journal* 2010; 9(1): 55-7.
5. Liu YI, Shin LK, Kamaya A, Jeffrey RB. An Unusual Imaging and Clinical Presentation of Papillary Thyroid Carcinoma. *J Ultrasound Med* 2008; 27(8): 1241-4.