

Primary Lacrimal Sac Lymphoma With Recurrence: A Case Report

Chiun Kian Chai, MD, Ing Ping Tang, MS, Tee Yong Tan, MS

Hospital Umum Sarawak, Jalan Tun Ahmad Zaidi Aduce, 93586 Kuching, Sarawak

SUMMARY

Primary lacrimal sac lymphoma is rare. The common clinical features are epiphora and medial canthal swelling which mimic nasolacrimal duct obstruction. Histological examination is therefore important to avoid delay in diagnosis and treatment. We report a case of primary lacrimal sac lymphoma in a 72-year-old female who developed a metachronous tumour at the hard palate one year after excision of the lacrimal sac tumour.

KEY WORDS:

Lacrimal sac lymphoma

INTRODUCTION

Primary lacrimal sac lymphoma is rare. It only accounts for 8% of all the lacrimal sac tumours and more than 80% of the patients are above 60 years^{1,2}. In view of its insidious presentation, many patients are diagnosed late, and suffered treatment delay. Since there is no universally accepted treatment modality, various modes of treatments are practised in many centres.

CASE REPORT

A 71-year-old female presented to otorhinolaryngology clinic, complaining of painless right nasal bridge swelling for two months. She did not complain of epiphora, nasal blockage or double vision. However she used artificial eye drops for bilateral eye dryness. Clinical examination revealed a well-defined, hard mass measuring 2.5x2cm at right medial canthus, which was fixed to the underlying bone. Lymph nodes were not palpable at cervical, axillary and inguinal regions. There was no hepatosplenomegaly.

Computed tomography (CT) of paranasal sinuses was performed and showed a subcutaneous enhancing lesion over the right medial canthus without any bony erosion (Fig.1). There was no evidence of frontal sinus or frontal recess involvement.

She then underwent excision biopsy. Intra-operative revealed a solid mass in the right lacrimal sac which was adherent to the nasal bone. A clear surgical plane was identified and the mass was completely excised.

The histopathological examination showed clusters of atypical lymphoid cells with vague follicle-like pattern and surrounded by sclerotic collagen bands (Fig.2).

Immunostaining confirmed diffuse large B cell Non-Hodgkin lymphoma. CD 3, CD 20 and leukocyte common antigen were positive.

She was referred to hematology department where staging CT scan and trephine biopsy demonstrated normal finding thus Ann Arbor stage 1. Hence she was offered chemotherapy but unfortunately she refused. She was then follow up regularly. One year after the surgery, she complained of right upper molar pain with swelling extending from gum to the hard palate. Biopsy confirmed diffuse large B cell Non-Hodgkin lymphoma. She finally agreed for chemotherapy and completed six cycle of CHOP regime. Radiotherapy was not given in view of possible side effects. After one year of chemotherapy, she is well without any recurrence.

DISCUSSION

Primary lacrimal sac tumour is a rare entity. Generally it is classified into epithelial and non-epithelial in origin, which constituted 73% and 27% respectively. Non-epithelial tumours are further subdivided into mesenchymal tumour, lymphoma, malignant melanoma and neural tumour. Among all these tumours, lymphoma comprises of only 8% which is extremely low¹. From the literature search, there were less than 50 cases of primary lacrimal sac lymphoma, of which more than 2/3 of it came from western countries^{2,3}.

Lacrimal sac lymphoma can present with medial canthal swelling, epiphora, diplopia, and nasal symptoms such as sinusitis or nasal obstruction depend on the spread of the disease³. Sjo LD *et al* reported that the commonest symptoms were epiphora (85%), followed by medial canthal swelling (79%) and dacryocystitis (21%)². In our case, the patient was asymptomatic, with only a painless right medial canthal swelling as presenting complain. Hence the diagnosis of osteoma was made initially, causing delay in diagnosis and treatment.

Computed tomography is important to assess the extent of lacrimal sac lymphoma. The tumour can appear homogenous or heterogenous³. In our case, the first CT scan was suggestive of benign lesion at nasal bridge and there were no signs suggestive of lymphoma. The CT scan also failed to detect any tumour at hard palate. Magnetic resonance imaging (MRI) would be more appropriate in this situation as it is superior to CT scan in assessing soft tissue. However, the patient was not arranged for MRI due to restraint of local resources.

This article was accepted: 11 March 2013

Corresponding Author: Chiun Kian Chai, Hospital Umum Sarawak, Jalan Tun Ahmad Zaidi Aduce, 93586 Kuching, Sarawak

Email: chiun_kian@yahoo.com.sg

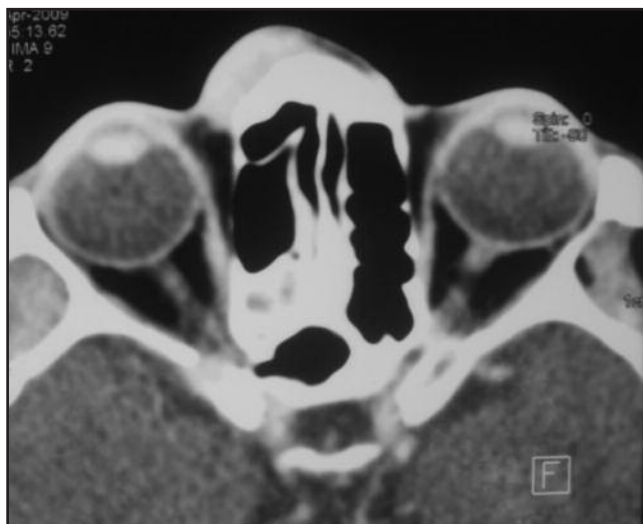

Fig. 1 : Computed tomography of paranasal sinuses showed a subcutaneous enhancing lesion over the right medial canthus without any bony erosion.

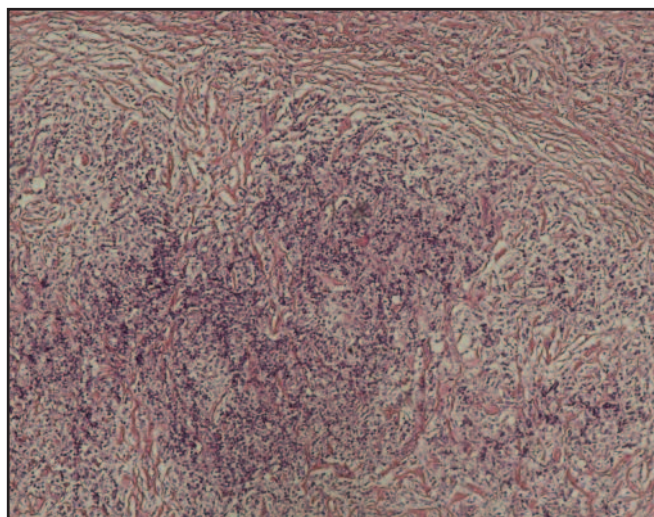


Fig. 2 : Histopathology showed clusters of atypical lymphoid cells with vague follicle-like pattern and surrounded by sclerotic collagen bands.

Tissue diagnosis and immunostaining are definite for lymphoma. Lymphoma can arise from lacrimal sac or ducts which are highly vascular and possess lymphoid tissue at its mucosa. Almost all the lacrimal sac lymphoma were B cell lymphoma, only few were T-cell^{2,3}. As in our case, the patient's histopathology showed diffuse large B cell lymphoma which was classified as aggressive or high grade lymphoma.

The management of primary lacrimal sac lymphoma is not well established. A well-organized research is limited by the rarity of the disease. The treatment modalities consist of surgery, radiotherapy, chemotherapy or combination. Most of the primary lacrimal lymphoma cases in the literatures were treated with radiotherapy with or without chemotherapy and surgery^{2,3}. However, in our case, only surgery was performed without other adjuvant therapy as patient refused. She developed metachronous tumour at hard palate one year later though there was no local recurrence at the primary site. As surgery alone is inadequate to control a systemic disease like lymphoma, chemotherapy is therefore recommended to prevent not only local recurrence but also for regional and distant involvement.

CONCLUSION

Primary lacrimal sac lymphoma is a rare entity. The common clinical features are epiphora and medial canthal swelling. Histological examination is important to avoid delay in the diagnosis. The treatment remains controversial, it mainly consists of surgery, radiotherapy, chemotherapy or combination. The present result suggests that complete excision in a localized primary lacrimal sac lymphoma is insufficient to achieve complete remission. Chemotherapy is recommended and regular follow up is mandatory.

REFERENCES

1. Parmar DN, Rose GE. Management of lacrimal sac tumours. *Eye (Lond)* 2003; 17(5): 599-606
2. Sjo LD, Ralfkiaer E, Juhl BR, *et al*. Primary lymphoma of the lacrimal sac: an EORTC ophthalmic oncology task force study. *Br J Ophthalmol*. 2006; 90(8):1004-9. Epub 2006
3. Scheffler AC, Shields CL, Shields JA, Demirci H, Maus M, Eagle RC Jr. Lacrimal sac lymphoma in a child. *Arch Ophthalmol*. 2003; 121(9): 1330-3