

# Outcome of Canal Wall Down Mastoidectomy: Experience in Sixty Three Cases

Asma binti Abdullah, MS ORL HNS, Shaharudin Mohamad Hashim, MS ORL-HNS, Muhammad Almyzan Awang, B.Aud (Hons), Lokman Saim, MS ORL-HNS

Universiti Kebangsaan Malaysia Medical Centre, Department of ENT, UKMMC, Jalan Yaacob Latiff, Bandar Tun Razak, Cheras, 56000, Kuala Lumpur, Wilayah Persekutuan, Malaysia

## SUMMARY

A canal wall down mastoidectomy (CWDM) is an effective technique for eradication of advanced chronic otitis media or cholesteatomas. A retrospective study was conducted at a Malaysian Tertiary Medical Center between June 1996 to December 2003 to evaluate the outcome of Modified Radical Mastoidectomy (MRM), a form of CWDM for patients with chronic active otitis media (OM) with cholesteatoma, chronic mastoiditis or chronic active OM with cholesteatoma and mastoiditis. All new cases of MRM which fulfilled the selection criteria were reviewed. The main outcome measures were the hearing outcome and status of dry ear postoperatively. A total of 84 patients had undergone CWDM. However only 63 patients (26 male, 37 female) were included for analysis. The age of the patients ranged between 5 months to 72 years (mean, 31years). The majority of the patients (86%) were adults and 9 (14%) were children. The ossicular chain was eroded in 91% (57 cases). There were 33 patients (53%) who showed no improvement of Air Bone Gap (ABG) closure while 16 patients (25%) had a post-operative improvement. The presence or absence of stapes suprastructure was found to be the major factor in determining the amount of ABG (Chi squared test,  $P = 0.025$  preoperatively and  $P = 0.031$  postoperatively). A dry ear was achieved in 78% of patients with 3% recurrence rate. In conclusion, the study showed that a proper MRM gave high percentage of dry ear and this procedure did not worsen the hearing.

## KEY WORDS:

Canal wall down mastoidectomy; mastoiditis; cholesteatoma; mastoid obliteration

## INTRODUCTION

There are two common surgical approaches in managing chronic active otitis media with or without cholesteatoma and chronic mastoiditis. These approaches are canal wall up mastoidectomy (CWUM) and canal wall down mastoidectomy (CWDM). In CWUM, removal of the middle ear and mastoid disease is performed with preservation of the posterior canal wall. Modified Radical Mastoidectomy (MRM) is one form of CWDM. In MRM, the posterior canal wall is taken down till the level of the facial nerve and the

floor of the mastoid cavity is continuous with the floor of the external canal. At the end of the operation, the mastoid cavity, epitympanum and external auditory canal are converted into a common cavity.

Several factors including the age, otologic findings and hearing status both in the diseased and contralateral ear are important considerations for choice of surgical procedure in chronic active otitis media. In general, factors that favour CWUM are in the cases of limited atticointral disease with minimal hearing loss, intact ossicular chain and in well pneumatized mastoid. Apart from this, patient with good compliance for follow up or in pediatric patient are also suitable for CWUM. On the other hand, relative indications for CWDM are patients with extensive disease (cholesteatoma or mastoiditis), poor hearing status, poor pneumatized mastoid and those cases with the presence of complications. Generally, the hearing results of CWUM are better than those of CWDM. In terms of residual or recurrent rate, many authors showed that the rates of residual and recurrent disease are increased with CWUM<sup>1</sup>.

The type of ossicular reconstruction done depends on the ossicular status. In our practice we used the classification described by Schuknecht<sup>2</sup>. In CWDM, the only choice of tympanoplasty is Type III (stapes columella and major columella), Type IV and Type V. In Type III-stapes columella tympanoplasty the graft is placed directly on the head of the stapes. Type III- major columella tympanoplasty can be performed when the stapes suprastructure are missing and the footplate is intact and mobile. In Type IV tympanoplasty when the stapes suprastructure is missing, the reconstruction can be performed by placing the graft directly on the stapes footplate. Type V tympanoplasty is a two staged procedure. The first staged if, the fixed footplate is identified, is a Type IV tympanoplasty. Later a second staged is performed in which the footplate is removed after a skin flap is elevated. Then a fat graft is placed in the oval window and the skin flap is replaced to cover the graft.

The aim of this study is to evaluate the outcome of canal wall down mastoidectomy for patients with chronic active otitis media (OM) with cholesteatoma, chronic mastoiditis or chronic active OM with cholesteatoma and mastoiditis.

This article was accepted: 13 December 2012

Corresponding Author: Asma binti Abdullah, Universiti Kebangsaan Malaysia Medical Centre, Department of ENT, UKMMC, Jalan Yaacob Latiff, Bandar Tun Razak, Cheras, 56000, Kuala Lumpur, Wilayah Persekutuan, Malaysia Email: asmaent@yahoo.com

## MATERIALS AND METHODS

A retrospective study was conducted at Malaysian Tertiary Medical Center from June 1996 to December 2003 to evaluate the outcome of modified radical mastoidectomy (MRM) for chronic active otitis media (OM) with cholesteatoma and chronic mastoiditis. Patients who underwent mastoid surgery as an approach to other surgery such as cochlear implant, translabyrinthine approach for acoustic neuroma and patient with profound sensorineural hearing loss were excluded. Only new patients who underwent MRM for chronic discharging ears were included and the patients needed to have preoperative hearing test report. There were two possible causes of chronic discharging ear were suppurative OM with cholesteatoma and/or chronic mastoiditis.

The case notes were reviewed for diagnosis, the presenting symptoms, intraoperative finding and the status of the ear post operatively. In the case where postoperative PTA was unavailable, patients were given followed up for hearing assessment. Regarding the assessment of hearing status, 3 pure-tone averages were used for bone and air thresholds at the frequencies of 0.5, 1, and 2 kHz. The average air conduction gain was obtained by subtracting the preoperative of the 3 pure tone average (i.e. 0.5, 1 and 2 kHz) for air conduction from the postoperative air conduction of the same average of 3 pure tone frequencies. Air bone gap closure was calculated by subtracting the postoperative preoperative air bone gap from the postoperative air bone gap of 3 pure tone average (i.e. 0.5, 1, and 2 kHz). The air bone gap closure was categorized into 3 categories<sup>3</sup>. Changes of ABG closure postoperatively were analyzed and patients were further grouped by 10 dB changes into: Improvement of ABG closure : < - 10 dB. No change: - 10 dB to 10 dB. Worsening of ABG closure: > 10 dB. The influence of the ossicular reconstruction/tympanoplasty and the absence of a stapes suprastructure on hearing results were analyzed. The data was analyzed using SPSS 11.5 for windows (SPSS, Chicago, IL). The level of statistical significance was set at  $p < 0.05$ .

## RESULTS

A total number of 84 patients underwent MRM within the study period. The indications for surgery include chronic suppurative otitis media with cholesteatoma and chronic mastoiditis. Out of 84, 21 (25%) patients were excluded because they were no preoperative hearing threshold test results. Therefore only 63 patients (26 male and 37 female) were included for retrospective analysis. The ages ranged between 5 months-72 years (mean, 31years). The majority of the patients (86%) were adults. Our patients were mainly Malays who account for 65% of the total, followed by Chinese (29%) and Indians(6%). Table I shows the presenting symptoms in these patients. Otorrhoea and reduced hearing were common in all age groups, 92% and 70%, respectively. Ten (16%) patients presented with complications (facial nerve palsy occurred in 3 patients, 2 cases of labyrinthine fistula, 2 cases of subperioestium abscess, 1 case of labyrinthitis, 1 case of extradural abscess and 1 case of cerebellar abscess). Six of the complications occurred in the presence of both disease and this was statistically significant (Chi square test  $P < 0.05$  (Table II).

Cholesteatoma alone was common finding in 36 cases (57%). Whereas 13 cases (21% had both (cholesteatoma and granulation tissue). The remaining 22% presented with chronic active OM with mastoiditis alone. Table 3 showed intraoperative finding according to the site of disease. Disease involvement was seen in both the mastoid antrum and mastoid cavity in more than half of all the cases. Fig. 1 showed status of the ossicles. The ossicular chain was eroded in 91% (57 cases). The malleus was eroded or absent in 54%, the incus in 87% and the stapes superstructure eroded or absent in 41%. The majority of patients had eroded or absent incus, eroded or absent malleus. They account for 34 cases (54%). Of the 91% with an interrupted ossicular chain (eroded or absent), 59% had an intact stapes and in 41% the stapes suprastructure were eroded but the footplate was intact.

A comparative analysis between preoperative and postoperative Air Bone Gap (ABG) is shown in Fig. 2. The distribution of patients classified according to ABG of 10 dB interval are similar preoperative and postoperatively. There was same number of patients with ABG of 10 dB and >41 dB pre and postoperatively. Overall, MRM did not change nor worsened the hearing status.

The majority of patients had advanced disease; 52 % of patients presented with air bone gap > 31 dB. 33 patients (53%) showed no improvement of ABG closure and 16 patients (25%) had a post-operative improvement of ABG closure. However, there were 14 patients (22%) had worsened of hearing postoperatively. The presence or absence of stapes suprastructure was found to be the major factor in determining the amount of ABG. There were 22 patients (73%) with ABG of <30dB had intact stapes suprastructure, while 18 (55%) of patients with ABG of >31dB had eroded/absent stapes suprastructure. This pattern remained the same postoperatively and was found to be statistically significant (Chi squared test,  $P = 0.025$  preoperatively and  $P = 0.031$  postoperatively).

Ossicular reconstruction based on Schuknecht Classification of Tympanoplasty.

Out of the 57 patients who underwent tympanoplasty, there were 27 patients with a type III tympanoplasty and 20 patients with a type IV tympanoplasty (Fig. 5). Six cases (9%) did not need any ossicular chain reconstruction because the ossicles remained intact. In ten other patients no ossicular reconstruction was done.

### *Post operative outcome.*

Dry ears was observed in 78% cases. There were 2 patients who presented with recurrence/residual, an overall recurrence rate of 3%. 12 patients (19%) had postoperative discharging ear secondary to the presence of granulation tissue.

## DISCUSSION

CWDM in the form of MRM is the preferred surgical procedure in surgery for chronic suppurative otitis media. The reasons for this are poor compliance of otologic follow

**Table I: Distribution of presenting symptoms**

Presenting symptoms	No	Percentage
Otorrhoea	58	92%
Earache	26	41%
Reduced hearing	44	70%
Ear bleeding	3	5%
Tinnitus	12	19%
Vertigo/giddiness	7	11%

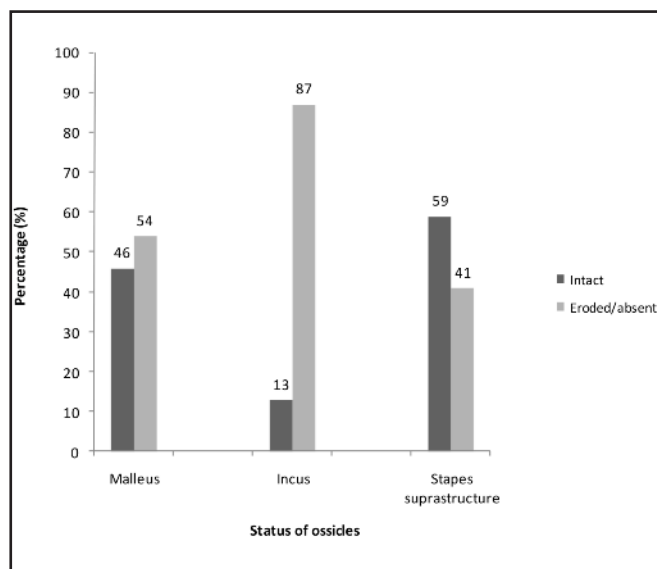
**Table II: The association between type of disease and complications**

Type of disease	Complications		Total
	Absent	Present	
Chronic active OM with cholesteatoma	33 (91.7%)	3 (8.3%)	36 (100%)
Chronic active OM with mastoiditis	13 (92.9%)	36 (7.1%)	14 (100%)
Chronic active otitis media with cholesteatoma and mastoiditis	7 (53.8%)	6 (46.2%)	13 (100%)
Total	53	10	63

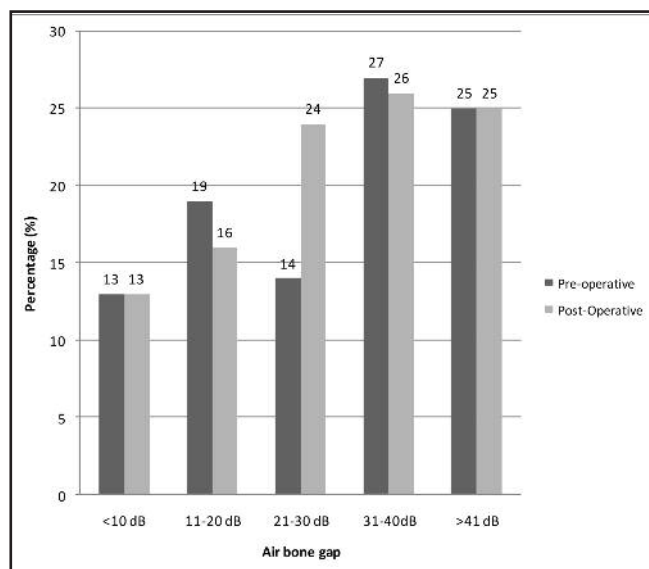
Chi square test = 11.258, P = 0.004

**Table III: Distribution of sites of disease found intraoperatively**

Site of disease	No	Percentage
Attic	31	49%
Mastoid antrum	36	73%
Mastoid cavity	45	72%
Middle ear cavity	30	48%



**Fig. 1:** Shows the status of malleus, incus and stapes suprastructure.



**Fig. 2:** The distribution of average pre and postoperative air bone gap.

up and usually patients present late with extensive disease, and their hearing status on the presentation poor. The racial distribution of the patients in this study reflects the racial distribution of the population in the country. In our series otorrhoea and reduced hearing were the most common presenting symptoms. Our findings in regard to the site of disease was consistence with Palva (1985) which showed that the mastoid antrum (>50%) was the commonest site of the

disease found intraoperatively<sup>3</sup>. Regarding ossicles involvement, the results of our series showed that incus is the most common ossicle affected followed by malleus. This is in agreement to past findings<sup>5, 6</sup>.

The present study showed that facial nerve palsy is the most common complication in patients with chronic otitis media who underwent MRM. This is contrary to other studies which

reported that meningitis was the most common intracranial complication<sup>7,8</sup>. Our series showed that there was significant association between type of disease and complications.

Wetmore *et al.* found in a series of 161 patients with cholesteatoma, the mean pure tone average remained unchanged after surgery<sup>9</sup>. They concluded that the presence or absence of the posterior canal wall had no influence on the hearing outcome. Regarding the air bone gap closure, this study showed 25% had improvement of ABG closure. Vartiainen *et al.* reported that after long-term follow-up, hearing level improved significantly ( $\geq 10$  dB) in one third of the patients, it remained unchanged in one third and deteriorated in the remaining one third<sup>10</sup>. Another study reported that in the long run, hearing improvement after cholesteatoma surgery was marginal, regardless of the surgical technique used<sup>11</sup>.

In contrast, Hirsch *et al.* demonstrated superior hearing outcome in a CWUM (76% versus 69% ABG closure less than 30 dB)<sup>12</sup>. The superior hearing results with CWUM may be related to less extensive disease and better preoperative hearing than to the surgical technique itself. The hearing loss can occur after middle ear or mastoid surgery probably due to changes in the structure of the middle ear or cochlear damage.

Regarding audiological result; in terms of tympanoplasty, our study did not demonstrate any significant difference between type III and type IV tympanoplasty. This result was similar to other studies<sup>13,14</sup>. The present study also demonstrated that the only factor significantly influencing audiological results is the stapes suprastructure integrity. We observed that 73% of patients with an intact stapes suprastructure had a preoperative ABG of less than 30 dB and for those with eroded/absent stapes suprastructure 55% had preoperative ABG more than 31 dB. This difference was maintained post operatively and was found to be statistically significant. Payal *et al.* reviewed 133 patients who underwent cholesteatoma surgery and concluded that a successful result is dependent on the presence of an intact stapes suprastructure and a well ventilated middle ear cavity. They reported that ABG of less than 30 dB was obtained in 62% of cases with intact stapes and for those with no stapes suprastructure this figure was only 27%. Others comparable results were also obtained for air bone gap in relation to the stapes suprastructure status<sup>15</sup>.

Seventy-eight percent of our patients had dry ears post operatively which is slightly lower than the study published by Payal *et al.* They reported 95% waterproof ears postoperatively<sup>2</sup>. Nineteen percent (12 patients) of post MRM discharging ear were due to granulation tissue which may be easily addressed by skin grafting or revision mastoidectomy. Our recurrence/residual rate of 3% was found to be almost similar to the other study<sup>3,4</sup>. The potential causes for discharging ear following CWDM include an insufficient meatoplasty, high facial ridge, dependent mastoid tip cells, incomplete mastoid air cell removal, and retained cholesteatoma.

Generally, residual/recurrence cholesteatoma has been found to appear significantly more frequent after CWUM than CWDM, rendering some form of second look surgery necessary<sup>16</sup>. On the other hand, the disadvantages of canal wall down mastoidectomy include cavity problems, such as continuous ear drainage, accumulation of keratin debris, frequent vertigo attacks following temperature or pressure changes, and difficulty in fitting a hearing aid. A number of materials, both biological and alloplastic, have been used for mastoid obliteration. Recent study suggests silicone blocks with bone pate and musculoperiosteal flaps may be useful materials in mastoid obliteration. They found the mean improvement in air-bone gap was about 12 dB ( $P < 0.05$ ), and the mean improvement in air-conduction was about 16 dB ( $P < 0.05$ )<sup>16</sup>. Another study used an inferior pedicle composite multifracted osteoperiosteal flap (CMOF) to obliterate the mastoid cavity and reconstruct the external auditory canal (EAC) to prevent the open cavity problems<sup>18</sup>. In this, the inferiorly based mucoperiosteum flap is used to reduce the size of mastoid cavity.

## CONCLUSION

The majority of patients had eroded or absent incus and malleus. The hearing outcome based on air bone gap closure was unchanged or improved (78%). The presence or absence of the stapes suprastructure influences the hearing result. A dry ear postoperatively was attained in 78% of patients with 3% recurrence rate. The study showed that a proper MRM gave high percentage of dry ears and this procedure did not worsen the hearing.

## ACKNOWLEDGEMENTS

We are grateful to all our ORL staffs especially to Mr. Azhan and Prof Sirjit Das for their assistance in preparing this article.

## REFERENCES

- Dennis, S. Analysis of eustachian tube functions by video endoscopy. *AM J Otol* 2000; 21: 602-7.
- Nadol JB, Schuknech HF. Ossiculoplasty and tympanoplasty combined with surgery for active chronic otitis media. *Surgery of the ear and temporal bone*. New York, Raven Press Ltd. 1993.
- Payal, M, Nicholas S, Richard L, Paul F. Long term outcome of modified radical mastoidectomy. *J Laryngol Otol* 2004; 118(8): 612-6.
- Palva, T. Surgical treatment of cholesteatomatous ear disease. *J Laryngol Otol* 1985; 99: 539-44.
- Joseph, PG, Siba PD. Canal wall down mastoidectomy: experience in 81 cases. *Otology & Neurotology* 2001; 22: 451-6.
- Kurien, M, Job A, Mathew J. Otogenic intracranial abscess: concurrent craniotomy and mastoidectomy: changing trends in a developing country. *Arch Otolaryngol* 1998; 124: 1353-6.
- Singh, B, Maharaj TJ. Radical mastoidectomy: its place in otitic intracranial complications. *J Laryngol Otol* 1993; 107: 1113-8.
- Kangsanarak, J, Fooanant S, Ruckphaopunt K et al. Extra cranial and intracranial complications of suppurative otitis media: report of 102 cases. *J Laryngol Otol* 1993; 107: 999-1004.
- Wetmore, RF, Konkle DF, Potsic WP and Handler SD. Cholesteatoma in pediatric patient. *Int J Pediatr Otorhi* 1987; 14: 101-12.
- Vartiainen, E, Nuutinen J. Long-term results of surgical treatment in different cholesteatoma types. *AM J Otol* 1993; 14(5): 507-1.
- Toner JG, Smyth GDL. Surgical treatment of cholesteatoma. A comparison of three techniques. *AM J Otol* 1990; 11: 247-50.
- Hisch, B, Kamerer D, Doshi S. Single-stage management of cholesteatoma. *J Otolaryngol Head Neck Surgery* 1992; 106: 51-54.

13. Mishiro, Y, Sakagai M, Okumura SI, Takeda N and Kubo T. Postoperative results for cholesteatoma in children. *Auris Nasus Larynx* 2000; 27: 223-6.
14. Daniela, S, Albert M. Cholesteatoma in children: techniques and results. *Int J Pediatr Otorhi* 2000; 52: 269-76.
15. Yukiko, L, Hisayo N, Yukako S and Kazuoki K. Hearing results of canal wall reconstruction tympanoplasty for middle ear cholesteatoma in children. *Int J Pediatr Otorhi* 2001; 60(1): 65-72.
16. Hassan, M, Hoda S. The canal wall up technique versus the canal wall down in tympanoplasty with mastoidectomy. *International Congress Series. Oto-Rhino-Laryngology* 2003; 1240: 105-8.
17. Sung, WC, Yong-Bum C, Hyong-Ho C. Mastoid Obliteration with Silicone Blocks after Canal Wall Down Mastoidectomy. *Clin Exp Otorhinolaryngol* 2012; 5(1): 23–27. Published online 2012 March 22. doi: 10.3342/ceo.2012.5.1.23
18. Cevat, U. Canal wall reconstruction and mastoid obliteration with composite multi-fractured osteoperiosteal flap. *Eur Arch Otorhinol* 2006; 263:1082–1086 DOI 10.1007/s00405-006-0164-1