

“Wide Skeletonization” Tubularised Incised Plate (TIP) Repair of Distal Penile Hypospadias with Narrow Urethral Plate

J Z Patankar*, S Fazal**, S Ubaidullah**, S Mukesh***

Millat Nursing Home, 141, S. V. Road, Millat School Complex, Jogeshwari (West), Mumbai – 400102, India.

SUMMARY

The importance of an adequate caliber neo-meatus for success of any hypospadias repair cannot be overstated. TIP repair incorporates a midline relaxing incision thus enabling tubularization but ultimately may not result in adequate neourethral caliber to avoid fistulas or meatal stenosis when the plate was narrow or flat, respectively. Objectives of this study is to evaluate results of a modification of TIP - “wide skeletonization” tubularized incised plate (TIP) – for repair of distal penile hypospadias with narrow urethral plate (UP), with regard to meatal stenosis and urethrocutaneous fistula.

Materials & Methods: Total of 108 hypospadias patients were operated upon. 26 were found to have distal penile Hypospadias with narrow UP (Narrow UP defined as any plate less than 6 mm width). 22 were selected for the study; All underwent “wide skeletonization” of the UP distally (“Wide Skeletonization” implies meatal based ventral “V” shaped incisions on outer margins of UP so as to incorporate generous portions of adjoining skin thereby allowing recruitment of penile and glandular skin lateral to the urethral plate to facilitate tubularization). Urethroplasty was fashioned over 10mm circumference of native UP with adjoining skin over a urethral stent. Repair was started with meatus first (calibrated over size 10-12F bougie). Meatal stitch was followed proximally with subepithelial tubularization of the neourethra; second layer comprising of spongiosal tissue. Barrier flaps were interposed between the neourethra and overlying glans and shaft skin closure, using inner prepuccial mucosal flap.

Results: Two patients had urethrocutaneous fistulae; one child had superficial dehiscence of glans. All three children were managed conservatively with no child requiring further surgery. All children had a good sized meatus and good stream of urine without any splaying.

Conclusions: “Wide Skeletonization” of the urethral plate distally (in a “V” fashion rather than “U”) gives an adequate caliber aesthetic neo-meatus especially in hypospadias children with narrow UP. It further helps in decreasing incidence of neourethral and/or meatal stenosis without increasing urethroplasty complication leading to an

excellent functional outcome. Whether this leads to better long term functionality of neourethra remains to be seen.

KEY WORDS:

Hypospadias, Urethral plate, Tubularized incised plate, Hypospadias repair.

INTRODUCTION

Tubularized incised plate (TIP) repair (Snodgrass Repair) has proven to be a very versatile repair for hypospadias repair¹⁻². Standard TIP comprises of ventral “U” shaped incisions along visible border of urethral plate running in parallel fashion Illustration (i). Urethral plate augmentation is done when the urethral plate is narrow and inelastic (Fig. A & Fig. B); requiring augmentation with free graft and tubularization. The importance of an adequate caliber neo-meatus for success of any hypospadias repair cannot be overstated. TIP repair incorporates a midline relaxing incision thus enabling tubularization but ultimately may not result in adequate neourethral caliber to avoid fistulas or meatal stenosis when the plate is narrow or flat, respectively.

OBJECTIVES

To evaluate results of a modification of TIP - “wide skeletonization” tubularized incised plate (TIP) – for repair of distal penile hypospadias with narrow urethral plate (UP), with regard to meatal stenosis and urethrocutaneous fistula.

DEFINITIONS

Narrow UP defined as any plate less than 6 mm width³⁻⁴. “Wide Skeletonization” implies meatal based ventral ‘V’ shaped incisions on outer margins of UP so as to incorporate generous portions of adjoining skin thereby allowing recruitment of penile and glandular skin lateral to the urethral plate to facilitate tubularization (Illustration (i)).

MATERIALS & METHODS

Period of study from January 2008 up to May 2011. Total of 108 hypospadias patients were operated upon. 26 were found to have distal penile hypospadias with narrow UP (Fig.

This article was accepted: 14 May 2013

Corresponding Author: Jahoorahmad Z Patankar, Millat Nursing Home, 141, S. V. Road, Millat School Complex, Jogeshwari (West), Mumbai – 400102, India. Email: zahoorp@yahoo.com

A & Fig. B). 22 were selected for the study; four patients having small glans (two circumcised) were deemed unfit for proposed "wide skeletonization" repair and were excluded from the study. Mean age 3.2 years (range 1-4). All had distal penile hypospadias with narrow UP; narrowest measuring 4 mm (10 cases); widest 6mm (4 cases); 5mm in the rest; mean width of UP 4.7mm. All underwent "wide skeletonization" of the UP distally (in a "V" fashion rather than "U") as described previously (Illustration (i)). Urethroplasty was fashioned over 10mm circumference of native UP with adjoining skin (Fig. C) over a urethral stent; size varied from 7.5 Fr (<2 yrs) to 10.5 Fr (> 2yrs). Although no dorsal slit was deemed necessary, four patients had a ledge dorsally which was gently incised to avoid obstruction to urinary flow. Repair was started with the meatus first (calibrated over a size 10-12F bougie). Upon adequate calibration redundant skin was excised. The meatal stitch was followed proximally with subepithelial tubularization of the neourethra in a subcuticular fashion without an indwelling stent. A second layer presumed to be comprising of spongiosal tissue that could be traced distally well into adjoining skin upto glans margin was sutured in an interrupted fashion so as not to constrict the calibre of neourethra. Barrier flaps were interposed between the neourethral and overlying glans and shaft skin closure, using the inner prepuce mucosal flap. Glansplasty was done in standard fashion. At end of procedure, urethroplasty could be easily stented with appropriate sized urethral stent with multiple perforations (Fig. D & Fig. E), fixed on glans stitch, connected to a paediatric urobag and kept in place for 10-14 days.

RESULTS

"Wide Skeletonization" of the urethral plate could be performed in all 22 children. Average hospital stay was 5 days (3-8 days). Two patients had urethrocuteaneous fistulae; one child had superficial dehiscence of glans. All three children were managed conservatively (both children with fistulae required meatal calibrations and dilatations in outpatient clinic for periods ranging from four to six weeks; other child with glans dehiscence healed with granulation tissue and epithelization). No child requiring re-hospitalization or re-do surgery. Importantly all children had a good sized meatus, slit-like (Fig. F & Fig. G), vertically oriented and in normal position with good urinary stream (Fig. H & Fig. I).

DISCUSSION

Snodgrass described hypospadias repair using tubularized incised urethral plate (TIP), the urethral plate incised in midline, to be widened and easily tubularized¹. The same group extended the use of TIP for repair of mid-penile and penoscrotal hypospadias².

In all tubularization procedures desired diameter of neourethral tube should be reached without any complications. TIP repair incorporates a midline relaxing incision thus enabling tubularization but ultimately may not result in adequate neourethral caliber to avoid fistulas or meatal stenosis when the plate was narrow or flat, respectively.

There remains a paucity of literature on a definition or set criteria evaluating urethral plate (UP) quality. The potential subjectivity and lack of agreement on UP quality seems to be present irrespective of level of the defect or surgeon experience³.

Holland and Smith were the first to evaluate outcomes according to plate configuration and width in a series of 48 patients⁴. Meatal stenosis occurred in 13% of their cases with a flat plate but did not occur when the plate was moderately or deeply grooved. In addition, fistulas developed in 55% of the boys when the plate was less than 8 mm wide before relaxing incision but in no case when the plate was 8 mm or greater. Based on these observations, they concluded that the midline relaxing incision enabled tubularization but ultimately did not result in adequate neourethral caliber to avoid fistulas or meatal stenosis when the plate was narrow or flat, respectively. In comparison, Nguyen and Snodgrass reported that TIP urethroplasty is a universal technique for primary hypospadias repair irrespective of the anatomical features of the urethral plate⁵. In their study of 159 patients they found no meatal stenosis and only a 2% fistula rate. No significant difference in results was predicted by plate configuration or width.

Healing after TIP occurs by secondary intention with creeping of the surface epithelium. Collagen deposition was increased in cases of UP \leq 6 mm in width. Post-TIP complications may increase in cases of narrow UP, especially with the neourethra and urethral incision > 2 cm in length⁶. Yazici M *et al* used a 'double vertical incision', in 8 rabbits and compared it with free skin graft, local flap and single vertical incision⁷. Based on the results obtained, they applied double vertical incision, a modification of tubularized incised plate urethroplasty popularized by Snodgrass, in 4 patients. The tubes were not distended, their long-term follow-up showed no complication and a urethra of the desired diameter was obtained. Snodgrass *et al* further found no contraindication to urethral plate tubularization with or without incision was found in 551 consecutive patients operated for distal hypospadias⁸.

Dorsal slit of the urethral plate with or without graft and its subsequent epithelization in terms of long term functionality of the neo-urethra remains to be seen. Although a good concept, its main drawback was the limitation imposed by the width of the urethral plate.

In our study we describe an alternative modification of an already established technique of hypospadias repair in select cases of distal penile hypospadias with narrow urethral plates. "Wide Skeletonization" of the urethral plate distally (in a "V" fashion distally rather than "U") sometimes so as to cut into the adjoining skin gives the dual advantage of creating an adequate caliber meatus (Upto size 10-12 Fr) helped to achieve a desired diameter of neo-urethral tube. More importantly a wider incision helps in tracing the "hidden spongiosal tissue" as it fans out distally. Just as the chordee fans out distally, the spongiosal tissue too fans out distally and is "hidden" beneath the adjoining skin rather than being "truly absent". Dissection just below the skin in a plane parallel to the corporal bodies preserves abortive corpora spongiosal tissue that is laterally splayed distal to




Fig. A : Distal Penile Hypospadias.




Fig. B : Narrow Urethral Plate.

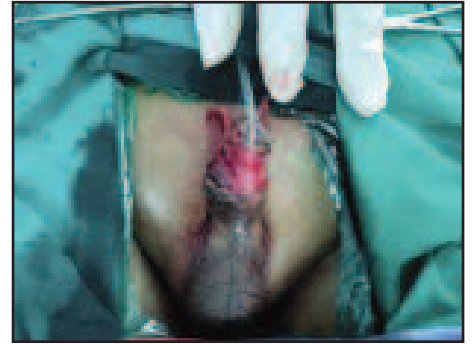

Fig. C : Wide Skeletonization of Urethral Plate along with adjoining skin.

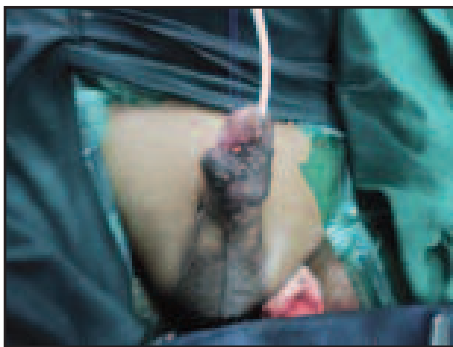

Fig. D : Completed Repair with stent.

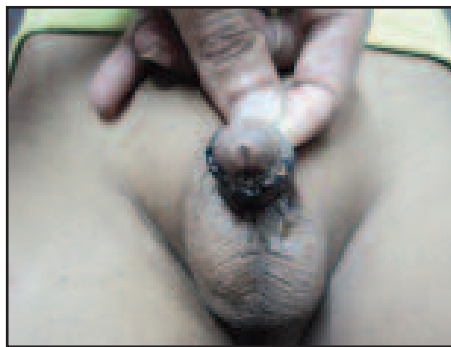


Fig. E : Epidermal Necrosis of skin cover.

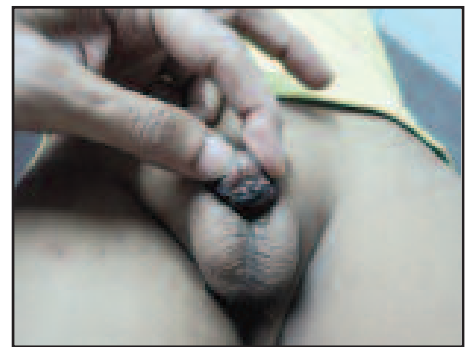


Fig. F : Wide caliber Meatus.




Fig. G : Good flow of Urine.




Fig. H : Passing urine from tip – successful repair!

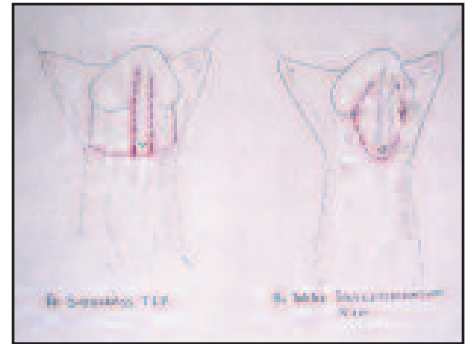


Illustration (i) :

- A. Snodgrass TIP: Comprises of ventral “U” shaped incisions along visible border of urethral plate running in parallel fashion.
- B. “Wide Skeletonization”: Implies meatal based ventral ‘V’ shaped incisions on outer margins of UP so as to incorporate generous portions of adjoining skin thereby allowing recruitment of penile and glandular skin lateral to the urethral plate to facilitate tubularization.

hypospadiac meatus⁹. A significantly better outcome is achieved with distal hypospadias, covering the neourethra with the mobilized corpus spongiosum (spongioplasty) or a flap, and experience¹⁰.

The importance of an adequate caliber neo-meatus for success of any hypospadias repair cannot be overstated. Creating the meatus first (with due calibration over a bougie) and subsequently proceeding proximally with the urethroplasty ensures a neourethra without risk of meatal stenosis. Calibration of neomeatus prior to starting the urethroplasty ensures an adequate calibre meatus. Also the meatus could be sited more easily as per glans configuration suitability which adds to anaesthetic outcome.

Healing after TIP occurs by secondary intention with creeping of the surface epithelium. Collagen deposition was increased in cases of UP \leq 6 mm in width. Post-TIP complications may increase in cases of narrow UP, especially with the neourethra and urethral incision > 2 cm in length⁶. Dorsal slit of the urethral plate with or without graft and its subsequent epithelization in terms of long term functionality of the neourethra remains to be seen. Again creating the meatus first and proceeding proximally with repair helps to prevent constriction of the neourethra thus ensuring unobstructed urine flow with good uroflowmetry. Furthermore incorporation of the abortive spongiosal tissue into the repair may prove useful for long term function of the neourethra.

CONCLUSION

“Wide Skeletonization” of the urethral plate distally (in a “V” fashion rather than “U”) gives an adequate caliber neo-meatus. It further helps in preventing neourethral and/or meatal stenosis without increasing urethroplasty complication leading to an excellent functional outcome. Whether this leads to better long term functionality of neourethra remains to be seen.

ETHICAL APPROVAL

Ethical approval has been obtained and the work has been approved by ethical committee.

REFERENCES

1. Snodgrass W. Tubularized incised plate urethroplasty for distal hypospadias. *J Urol* 1994; 151: 464-2.
2. Snodgrass W, Koyle M, Manzoni G, *et al*. Tubularized incised plate urethroplasty for proximal hypospadias. *J Urol* 1998; 159: 2129-3.
3. Yaser El-Hout, Luis HP Braga, Joao L. Pippi Salle, Katherine Moore, *et al*. Assessment of urethral plate appearance through digital photography: Do pediatric urologists agree in their visual impressions of the urethral plate in children with hypospadias? *J Pediatr Urol*. 2010 Jun; 6(4): 294-300
4. Holland AJ and Smith GH. Effect of the depth and width of the urethral plate on tubularized incised plate urethroplasty. *J Urol* 2000; 164: 489.
5. Nguyen MT, Snodgrass WT, Zaontz MR. Effect of urethral plate characteristics on tubularized incised plate urethroplasty. *J Urol*. 2004 Mar; 171(3): 1260-2.
6. Cooper CS, Noh PH, Snyder HM 3rd. Preservation of the Abortive Spongiosum in Hypospadias Repair. *Urology*. 2001 Feb; 57(2): 351-4.
7. Yazici M, Copcu E, Etensel B, *et al*. Comparison of Double Vertical Incision with Various Tubularization Techniques and Its Clinical Application. *Urol Int* 2003; 71: 299-305.
8. Snodgrass WT, Bush N, Cost N. Tubularized incised plate hypospadias repair for distal hypospadias. *J Pediatr Urol*. 2010 Aug; 6(4): 408-13.
9. Baskin LS, Ebbers MB. Hypospadias: anatomy, etiology, and technique. *J Pediatr Surg*. 2006 Mar; 41(3):463-72.
10. Sarhan OM, El-Hefnawy AS, Hafez AT, *et al*. Factors affecting outcome of tubularized incised plate (TIP) urethroplasty: single-center experience with 500 cases. *J Pediatr Urol*. 2009 Oct; 5(5): 378-82.