

# Chronic Tibial Osteomyelitis in Children. A Case Review at Hospital Tengku Ampuan Afzan, Kuantan

**Mohd Shukrimi Awang, MMed (Ortho)\*, Mohd Ariff Sharifudin, MMed (Ortho)\*, Zamzuri Zakaria, MS (Ortho)\*, Mai Nurul Ashikin Taib, MMed (Paediatrics)\*\***

\*Department of Orthopaedics, Traumatology and Rehabilitation, \*\*Department of Paediatrics, Kulliyyah (Faculty) of Medicine, International Islamic University Malaysia, 25150 Kuantan, Pahang, Malaysia

### SUMMARY

Osteomyelitis in children has various clinical manifestations causing diagnostic and therapeutic difficulties. Inappropriate treatment of acute osteomyelitis may lead to chronic, serious and complicated condition. Chronic osteomyelitis continues to be a major cause of morbidity and disability in children living in developing countries. We present three cases of tibial osteomyelitis that have different presentations and sequelae. Our intention is to alert our colleagues, particularly primary physicians, regarding the variety of presentation and the importance of early diagnosis and treatment to reduce the risk of morbidity following osteomyelitis.

### KEY WORDS:

*Chronic osteomyelitis, ipsilateral vascularized fibular graft, paediatric, tibia.*

### INTRODUCTION

Osteomyelitis in children continues to cause diagnostic and therapeutic difficulties. The clinical manifestations may vary. The signs and symptoms of infection are not always present. The clinical features of bony tenderness, limp or muscle spasm should raise suspicion of osteomyelitis, possibly with pyrexia and malaise. Inappropriate treatment of acute osteomyelitis may lead to chronic, serious and complicated condition. Chronic osteomyelitis continues to be a major cause of morbidity and disability in children living in developing countries. We present three cases of tibial osteomyelitis that have different presentations and sequelae. The intention of this article is to alert our colleagues, especially primary physicians, regarding the variety of presentations and the importance of early diagnosis and treatment, hence to reduce risk of morbidity following osteomyelitis.

### CASE REPORT

#### CASE 1

An 11-year-old Malay boy presented with boil like lesion with a swelling over the medial aspect of his right upper tibia. It was associated with mild pain and low-grade fever. There was no preceding trauma or fall. He was started on a week of oral antibiotics at a district hospital, but later opted for a traditional healer when his condition was not improving. He was referred to our centre only after a month for further

management. He was noted to have a diffuse swelling of his right upper tibia with boils like lesion present on top of the lesion. It was warm with mild tenderness. His right knee motion was restricted. His erythrocyte sedimentation rate (ESR) was 90mm/hr. Blood culture and sensitivity was negative. Neither open biopsy nor bony aspiration was done. Plain radiograph and MRI showed features of osteomyelitis involving the proximal aspect of right tibia (Fig. 1).

Patient was given two weeks of intravenous, followed by another six weeks of oral Cloxacillin. No surgical intervention performed on him. His condition improved following treatment. He was able to continue his daily activity as other normal school children six month following initiation of treatment. At 18 months, plain radiograph showed evidence of a complete recovery (Fig. 2).

#### CASE 2

A nine-year-old aboriginal girl presented with history of skin lesion, pain and swelling of her right leg for one-month duration. There was no history of trauma or fall prior to the onset. She received an initial treatment at a local clinic, in which "incision and drainage" was done twice over her leg. She also received a one-week course of antibiotic. She was referred to us for further management after no improvement was observed. Upon admission, she was noted to have a diffuse swelling of the whole right leg, with a sinus discharge at the medial aspect of her lower leg. ESR level was raised to 80mm/hr. Plain radiograph show lytic lesions with pathological fracture of the distal tibia (Fig. 3a and 3b).

Surgical debridement and curettage of the affected bone was performed. The culture grew *Staphylococcus aureus* species, which was sensitive to Cloxacillin. She was given a course of antibiotic for two months. Her condition improved clinically, and evidence of sclerotic repair of the bone and union of the pathological fracture was observed on plain radiographs (Fig. 3c). Unfortunately, she did not turn up for further follow-ups.

#### CASE 3

An 18-month-old baby girl was referred for pain, diffuse swelling of her left leg, and fever following a fall from a chair six days prior to admission. There were increments in her white cell count of 16,000, ESR of 95mm/hr and C-reactive protein (CRP) of 30g/dl. Incision and drainage was performed and 50cc of pus was drained out. Culture and sensitivity grew *Staphylococcus aureus*, which was sensitive to Cloxacillin.

*This article was accepted: 13 October 2014*

*Corresponding Author: Mohd Ariff Sharifudin, Department of Orthopaedics, Traumatology and Rehabilitation, Kulliyyah (Faculty) of Medicine, International Islamic University Malaysia, 25150 Kuantan, Pahang, Malaysia Email: ariffs@iiu.edu.my*

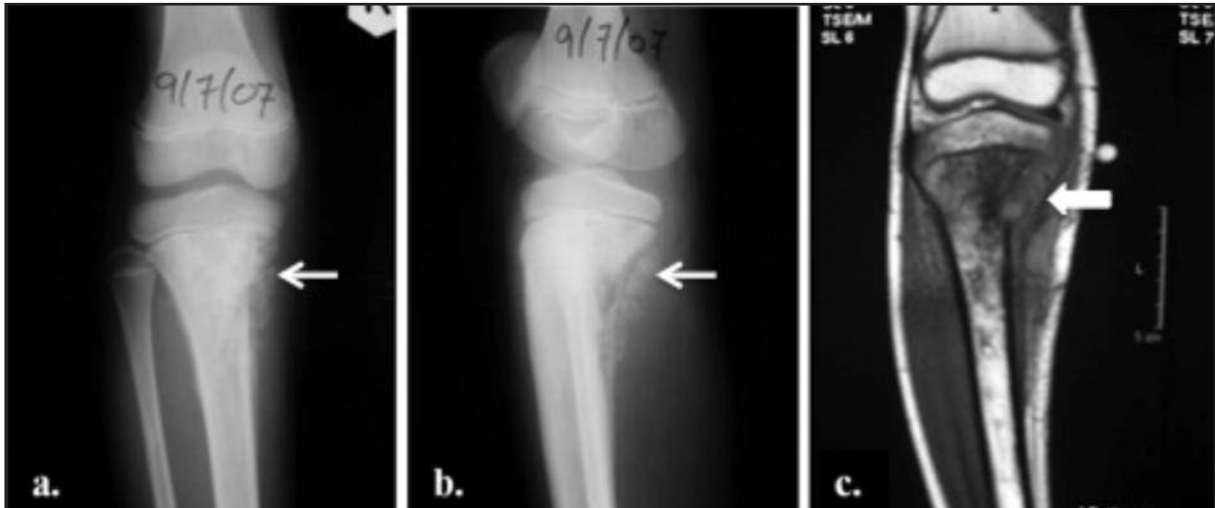

Fig. 1: Case 1: Anteroposterior (a) and lateral (b) plain radiographs of the proximal right tibia showing osteolytic lesion involving the metaphyseal region with periosteal reaction (white arrow). Tumour-like osteolytic lesion was seen on MRI (white arrow) (c).

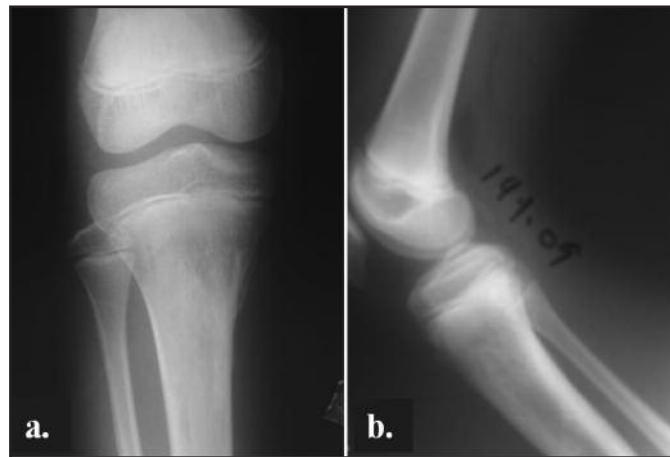

Fig. 2: Case 1: Anteroposterior (a) and lateral (b) plain radiographs at 18 months after treatment showing a complete recovery.

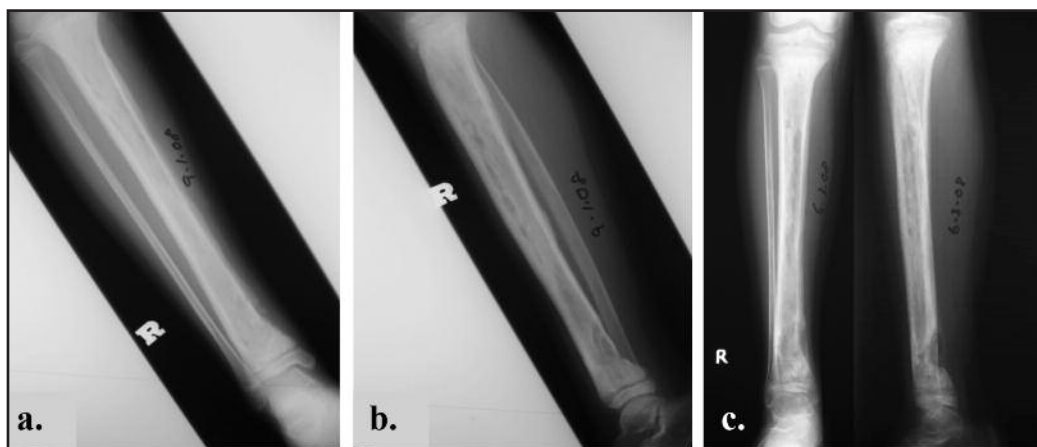
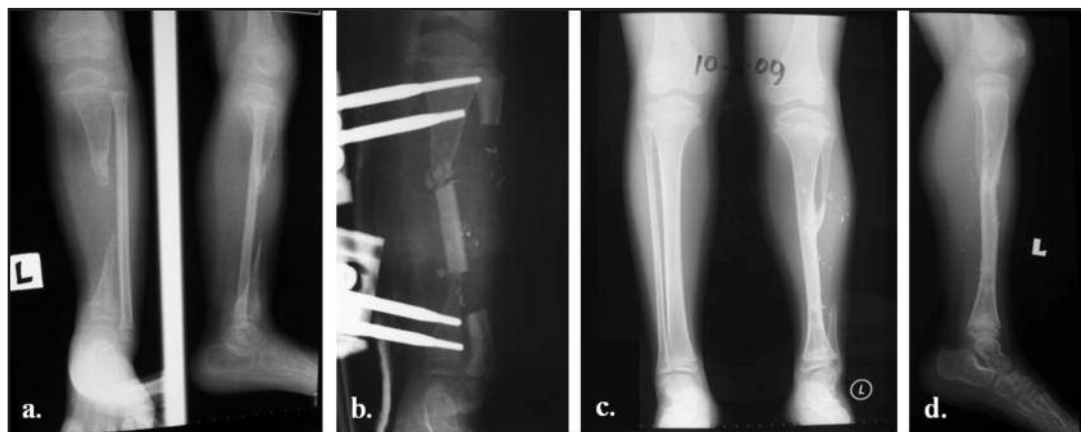

Fig. 3: Case 2: Anteroposterior (a) and lateral (b) plain radiographs at presentation, showing a lytic changes and pathological fracture of posteromedial aspect of the lower tibia. Two months, following treatment, sclerotic changes and union of pathological fracture was observed (posteromedial cortex) on plain radiograph (c).



**Fig. 4:** Case 3: Anteroposterior and lateral (a) plain radiographs showed segmental bone loss at mid-shaft of the tibia, and after ipsilateral vascularised fibular graft with external fixation (b). The graft hypertrophied and corrected the length discrepancy and varus deformity of the leg (c and d).

Her clinical condition worsens despite intravenous antibiotic. Plain radiograph at one month of presentation showed evidence of pan-osteomyelitis of the tibia complicated with pathological fracture. Patient was put on full length cast and antibiotic was continued for another two months. However, subsequent plain radiograph showed an approximately 5cm bony resorption in the mid-shaft of the tibia (Fig. 4a). At this point of time, patient remained clinically aseptically. She started back to walk without any form of immobilization, causing varus deformity of the ankle. The affected leg was also short of about 3cm compared to the contralateral leg.

We performed reconstruction of the tibial defect at six months after infection had clinically settled. This involved the isolation of pedicle fibular graft from the ipsilateral leg, removal of fibrous tissue from the tibial defect, and transfer of 5cm fibular graft to bridge the tibial gap. External fixator was applied and was kept for two months (Fig. 4b), which was then changed to full length cast for another six weeks. Patient showed excellent recovery from the surgery. On her recent follow up at two years after surgery, there was no limb length discrepancy and the transferred fibula graft had become hypertrophied. The varus deformity of the ankle was also corrected (Fig. 4c).

**DISCUSSION**

Paediatric musculoskeletal infections remain an important cause of morbidity. Recent prospective studies indicate uncomplicated osteomyelitis can be treated by three to four weeks of antibiotics.<sup>1</sup> However, a small group of children will have an overwhelming disseminated infection causing significant morbidity, like in our third case. Hematogenous osteomyelitis may lead to extensive bone necrosis and formation of sequestra, with resultant pseudarthroses and segmental bone defects.

In this case review, we highlighted three cases of chronic osteomyelitis. Even though all the cases had similar presentations at initial stage, however, their clinical progression varies. It is important to alert primary care physicians and also orthopaedic specialist and district hospital regarding their possible sequelae and complications

that can lead to severe morbidity to the patients. In all cases, infection started at the metaphyseal region; two involved proximal tibial (case 1 and 3), and one distally (case 2). *Staphylococcus aureus* were isolated in two of the cases, whereas no specific organism was isolated in the other case. This is consistent with findings by Yeargan *et al.*, in which 78% of their cases are positive of this organism.<sup>2</sup>

Recent studies have demonstrated a 90% response rate to medical therapy alone when treatment was initiated promptly and continued for an appropriate time.<sup>1</sup> In chronic osteomyelitis, the indications for surgical treatment are the presence of local pain and swelling with or without drainage, the presence of osteolytic lesions or sequestrum, or both. However, it has a risk of damaging the physis if the osteomyelitis involved cavitation near to it. Reinehr *et al.* found that their diagnostic procedure was useful to reduce the rate of surgery in chronic osteomyelitis.<sup>3</sup> They reserve surgical treatment only for patients presented with abscess, septic arthritis or frank sequestrum. In case 1, the patient was treated with antibiotic only, and had a full recovery. There was no residual infection or deformity. With the presence of boil-like lesion over the proximal tibia, it was more suggestive of infection rather than tumour. Hence, no biopsy was performed at initial presentation. Patient also responded very well with antibiotic treatment. It was supported by improvement in clinical findings and reduction of ESR. In case 2, patient was surgically treated with debridement of the sequestrum and drainage of the pus. Intra-operative samples were obtained and assisted in identifying the causative organism. With correct and appropriate duration of treatment, the patient showed signs of recovery till she lost from our routine follow-up.

Many authors had described the treatment of osseous defect using either ipsilateral or contralateral vascularized fibular graft since Albert first described it in 1877.<sup>4</sup> Tibialisation of the fibular with some preservation of the surrounding muscles attachments retained the vascularity of the graft. This method does not require performing a micro-anastomosis between the graft pedicle and the recipient site. Zahiri *et al.* successfully used this method to treat chronic osteomyelitis of the entire tibial shaft in nine children.<sup>5</sup>

Surgery was performed in three stages. In case 3, we transferred the ipsilateral fibular and slotted it in the middle of the resected tibial shaft, and hold it with an external fixator for six weeks. Unlike Zahiri method, we did it in single stage procedure using a unilateral external fixator instead of Ilizarov frame. The transferred fibular graft showed a complete fusion and hypertrophied. Patient recovered well and limb length discrepancy was corrected.

#### CONCLUSION

Appropriate administration of antibiotic plays an important role in managing acute osteomyelitis to avoid a progression to chronic osteomyelitis in children. Surgical debridement together with appropriate antibiotic is important factor in treatment of chronic osteomyelitis in children. Surgical reconstruction of bony defect using vascularised fibular graft for chronic osteomyelitis of tibial in children is reserved for severe case due to complexity of the procedure and the need of technical experts.

#### REFERENCES

1. Jagodzinski NA, Kanwar R, Graham K, *et al.* Prospective evaluation of a shortened regimen of treatment for acute osteomyelitis and septic arthritis in children. *J Pediatr Orthop* 2009; 29(5): 518-25.
2. Yeargan SA 3rd, Nakasone CK, Shaieb MD, Montgomery WP, Reinker KA. Treatment of chronic osteomyelitis in children resistant to previous therapy. *J Pediatr Orthop* 2004; 24(1): 109-22.
3. Reinehr T, Burk G, Michel E, *et al.* Chronic osteomyelitis in childhood: is surgery always indicated? *Infection* 2000; 28(5): 282-6.
4. Atkins RM, Madhavan P, Sudhakar J, *et al.* Ipsilateral vascularised fibular transport for massive defect of the tibia. *J Bone Joint Surg Br.* 1999; 81(6): 1035-40.
5. Zahiri CA, Zahiri H, Tehrani F. Limb salvage in advanced chronic osteomyelitis in children. *Int Orthop* 1997; 21(4): 249-52.