

Combined Laparoscopic and Thoracoscopic Repair of A Large Traumatic Diaphragmatic Hernia: A Case Report

Zubaidah Nor Hanipah, MS(Surgery) *, Azuawarie Amir, MBBS**, Ong Kheng Wah, MS(Surgery) *, Tikfu Gee, MS(Surgery)*

*Department of Surgery, Faculty of Medicine and Health Sciences, University Putra Malaysia, Selangor, Malaysia, **Hospital Serdang, Selangor, Malaysia

SUMMARY

Traumatic diaphragmatic hernia is a well known complication of blunt trauma to the abdomen and thorax. In the acute setting, laparotomy is mandatory. In this current era, this condition can be managed with minimally invasive surgery. We hereby report a case of delayed large left diaphragmatic hernia that was repaired with a combination of laparoscopic and thoracoscopic approach.

KEY WORDS:

Diaphragmatic hernia, laparoscopic, thoracoscopic, trauma

INTRODUCTION

Mechanisms of traumatic diaphragmatic hernia have been well described after blunt injury to the chest and abdominal cavity. Diaphragmatic ruptures can occur from 0.8% to 7.0% of blunt abdominal trauma, with left hemi diaphragm involvement the commonest; a ratio of 9:1.^{1,2}

Conventionally, laparotomy is indicated in all patients with other associated injuries in the acute setting. However, when the diagnosis is missed during early post trauma period, thoracotomy and repair were recommended. In this present era of minimally invasive surgery, laparoscopy is a useful means to treat diaphragmatic rupture even during the acute phase.^{1,2} Here, we report a case with a delayed large left diaphragmatic hernia that was repaired with a combination of laparoscopy and thoracoscopic approach.

CASE REPORT

A 30 year old gentleman presented to the emergency department with sudden onset breathlessness on exertion. He had a history of left rib fracture due to motor vehicle accident four years ago, but otherwise asymptomatic prior to current complaint. On examination, the left chest had reduced breath sounds and his abdomen was scaphoid but non tender. Plain chest x-ray showed loops of bowel in the left thorax. Computerized tomography of the thorax and abdomen revealed large left diaphragmatic hernia with bowel occupying almost all the left thorax (figure 1).

Elective laparoscopic and thoracoscopic repair of incarcerated diaphragmatic hernia with mesh was performed. He was put in supine position with slightly left

sided up. Five trocars were placed; 1x12mm (camera port at infra umbilicus) and 4x5mm (two ports at right upper quadrant, one port at left 4th intercostal space anterior axillary line and another port at the lateral aspect of left upper quadrant).

The omentum, small bowel and transverse colon were found densely adhered into the left hemithorax through the left anterolateral diaphragmatic hernia that measured 10x5 cm (figure 2). A combination of blunt and sharp dissection was used to reduce the hernia content to the abdominal cavity. Thoracoscopic approach was used to release the dense adhesion at the upper lobe of the lung to the left lateral thoracic wall. Upon reduction, the hernia defect was then closed with ethibon 2/0.

Before placing the mesh, the anaesthetist increased the tidal volume to expand the collapsed left lower lobe of the lung and a chest drain size 28F was placed in the left pleural space. Composite mesh 10x15cm was reinforced with secure strap tackers. Portex drain size 27F was placed at left sub diaphragmatic space.

The patient was then transferred to the intensive care unit (ICU) postoperatively. He was extubated on day one in ICU and on postoperative day two, he was transferred out to the general ward. Chest x-ray immediate post-operative showed expansion of the left lung with minimal pleural effusion. He was discharged on post-operative day six. He recovered well and during clinic follow up to six months, there was no evidence of recurrence or infection.

DISCUSSION

Chronic traumatic diaphragmatic hernia is conventionally repaired using the thoracotomy approach, reduction of intra-abdominal content and closure of the defect primarily. Where else in acute cases, a laparotomy is performed to reduce and repair the diaphragmatic hernia defect. In 1976, thoracoscopy was used to evaluate diaphragmatic injuries.³ Laparoscopy was used in a case series of suspected diaphragmatic injury in 1984.⁴

Currently, more surgeons prefer to use a thoracoscopic approach to repair chronic diaphragmatic hernias. Here, we have described a combined approach of laparoscopy and

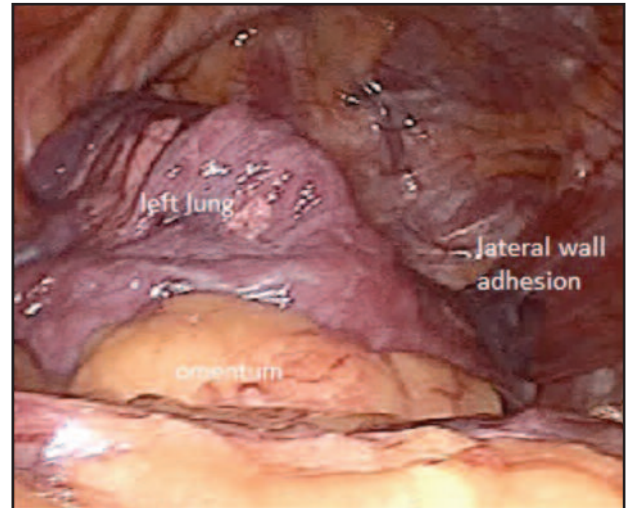
This article was accepted: 28 November 2014

Corresponding Author: Zubaidah Nor Hanipah, Department of Surgery, Faculty of Medicine and Health Sciences, University Putra Malaysia, 43400 UPM Serdang, Selangor, Malaysia Email: zuby_nh@yahoo.com

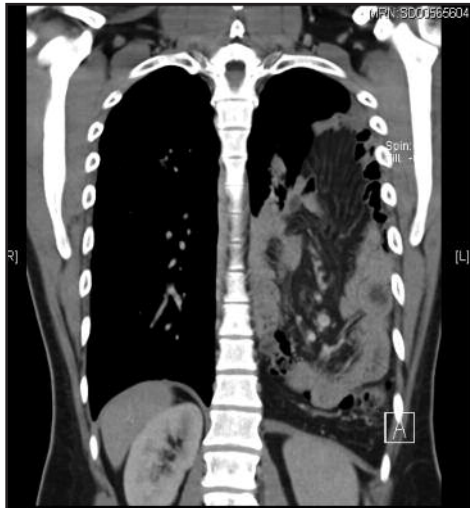

Figure legends

Fig. 1: CT Thorax shows large left diaphragmatic hernia with bowel occupying the left thorax



Intra-operative picture

Fig. 2: Large defect in the left hemi-diaphragm adjacent to the left lobe of liver (10x5cm). Adhesions of the hypotrophic left lung and the intestines indicates chronicity.

thoracoscopy in repairing a large traumatic diaphragmatic hernia. A combination of approaches enables reduction of large content into abdomen with minimal bleeding and contamination.

The closure of the hernia defect is usually done with simple closure. But in cases of large chronic diaphragmatic hernia, primary closure of the defect is not feasible. Most surgeons report the need of mesh repair for large diaphragmatic defects.⁵ Choice and size of the mesh is crucial in any case. We used composite mesh to close the large defect. Other meshes are available as well. Erosion of mesh into the bowel and infection are the major concerns.

Suturing the mesh to the diaphragm is possible, nevertheless, it is hard when the angles are awkward. Endoscopic hernia stapler can also be utilized to close the hernia defect.⁵ We fixed the mesh with laparoscopic tackers in our case. Laparoscopic tackers are fast and easy to use, but the only concern when the hernia defect is on the left side and its chronic large defect. The possibilities of injuring the pericardium during inward pressure is present. Hence, tacking the mesh to the edge of hernia has to be done with caution.

CONCLUSION

Laparoscopic approach is safe, feasible and effective in the treatment of large traumatic diaphragmatic hernias. Combination of laparoscopic and thoracoscopic approaches are recommended in difficult large diaphragmatic hernia repair.

REFERENCES

1. Rush VW, Ginsberg RJ. Chest wall, pleura, lung and mediastinum. In Schwartz SI, Shires GT, Spenser FC, Daly JM, Fischer JE, Galloway AC. Principle of Surgery, 7th edition, New York: McGraw-Hill Company, 1999: 685.
2. Paisal P. Repair of chronic post traumatic diaphragmatic hernia by laparoscopic surgery. The Thai Journal of Surgery 2001; 22: 11-4.
3. Jackson AM, Ferreira AA. Thoracoscopy as an aid to the diagnosis of diaphragmatic injury in penetrating wound of left lower chest: a preliminary report. Injury 1976 Feb; 7(3): 213-7.
4. Adamthwaite DN. Traumatic diaphragmatic hernia: a new indication for laparoscopy. Br J Surg 1984 Apr; 71(4): 315.
5. Frantzides CT, Madan AK, Zografakis J, Smith C. Laparoscopic Repair of incarcerated diaphragmatic hernia with mesh. J Laparoendosc Adv Surg Tech A 2007 Feb; 17(1): 39-42.