

# The bleeding umbilicus: An uncommon presentation of endometriosis

Nurjasmine Aida Jamani, MMed<sup>1</sup>, Zalina Nusee, MMed<sup>2</sup>, Hamizah Ismail, MMed<sup>2</sup>

<sup>1</sup>Department of Family Medicine, Kulliyyah of Medicine, International Islamic University Malaysia, Jalan Sultan Ahmad Shah, Kuantan Pahang, Malaysia, <sup>2</sup>Department of Obstetrics and Gynaecology, Kulliyyah of Medicine, International Islamic University Malaysia, Jalan Sultan Ahmad Shah, Kuantan Pahang, Malaysia

### SUMMARY

**Dysmenorrhea is a common presentation in women of reproductive age in primary care. It can negatively affect the quality of life of a woman and restrict her daily activities. Endometriosis is the most common diagnosis for secondary dysmenorrhea. However, cutaneous endometriosis is an uncommon presentation of endometriosis. It requires a thorough history, physical examination and histological findings for definitive diagnosis. This paper reports an interesting case of a 47-year-old woman with primary cutaneous umbilical endometriosis and its management. Her final diagnosis was primary umbilical endometriosis with Stage 3 endometriosis based on the patient's history, clinical and surgical findings. The patient was discharged well on day three of operation and has been well since then with no signs of recurrence.**

### INTRODUCTION

Dysmenorrhea is a common complaint seen in primary care. The prevalence varies between 16-81% between countries.<sup>1</sup> It can be classified into primary and secondary dysmenorrhea. Primary dysmenorrhea is defined as painful menses in the absence of any pathology. In contrast, secondary dysmenorrhea presents with specific pelvic pathology. The latter requires further evaluation and investigation.

Endometriosis is the most common cause of secondary dysmenorrhea. It is defined as the presence of endometrial tissue gland outside the uterine cavity. It typically affects other pelvic organs such as the ovaries, fallopian tubes, uterine ligaments, and pelvic walls.<sup>2</sup> The prevalence of endometriosis has been reported to be 10% in the general female population, predominantly among women of reproductive age.<sup>3</sup> They can present with dysmenorrhea, deep pelvic pain and dyspareunia. Endometriosis can also occur elsewhere such as in the thorax, gastrointestinal tract and skin (cutaneous).

Cutaneous endometriosis is the presence of endometrial tissue in the skin. The most-reported site is the umbilicus, around 30-40% which could be primary or secondary.<sup>2</sup> Primary cutaneous umbilical endometriosis (UE) is rare compared to secondary umbilical endometriosis. In secondary UE, seedling happens at a surgical scar after an abdominal surgery.

Despite primary UE is rare and this is known to gynaecologists, UE is unfamiliar to others, especially the primary care physicians. Hence, we report a case of a 47-year-old woman presenting with dysmenorrhea and cyclical bleeding from the umbilicus.

### CASE REPORT

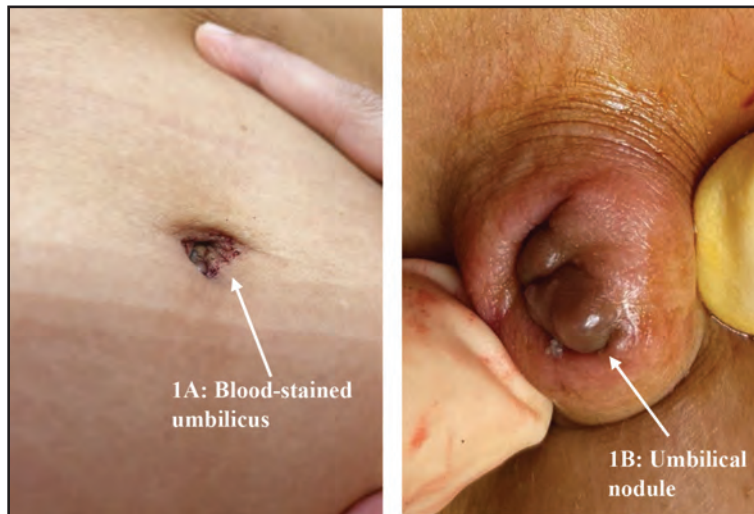
A 47-year-old woman presented with dysmenorrhea for one year. Previously, she never had any history of dysmenorrhea during her younger days. The pain usually presented before menses and sometimes she had fainting spells. On each menstrual cycle, she also noticed minimal blood-stained over her umbilicus but did not notice any nodule or mass. She attained menarche at the age of 12 years and has had regular menses since then. She has no menorrhagia or dyspareunia. She had no medical illness and has never done any surgery. She had three children, and all were delivered vaginally.

Her family physician gave her regular analgesics. She initially responded to analgesics but later, the pain became severe. She was then referred to a gynaecologist for further assessment.

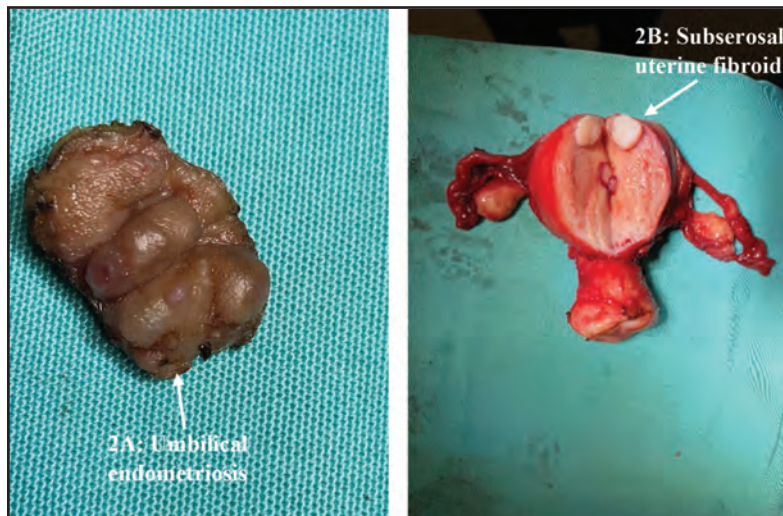
On examination, she was on day 3 of menses. She was not pale with normal vital signs. Abdominal examination was soft and non-tender. A violaceous coloured nodule was noted, measuring 1.0x0.8cm in the umbilicus with blood-stained (Figure 1A and 1B). No active bleeding was seen and no pelvic mass was palpable. Other examination was unremarkable, including vaginal examination.

Transabdominal and transvaginal ultrasound scans showed a normal size anteverted uterus and no adnexal mass seen. Blood investigations were normal except for raised serum CA 125 (228 U/ml). A diagnosis of severe dysmenorrhea secondary to endometriosis with cutaneous involvement was made. Initially she was treated with oral Dienogest 1 tablet daily for five months. Her symptoms slightly improved for three months but later recurred. She was then counselled for surgical treatment and agreed to it.

Umbilical nodule excision and total abdominal hysterectomy with bilateral salpingo-oophorectomy (TAHBSO) were performed (Figure 2A). Intraoperatively, the uterus was normal in size, with endometriosis deposits seen posteriorly.



**Fig. 1:** (A) Bloodstain at the umbilicus during menstrual cycle and (B) closed-up image of the violaceous umbilical nodule.



**Fig. 2:** (A) Excised umbilical nodule with endometriosis (white arrow). (B) Presence of subserosal uterine fibroid (white arrow).

There was a presence of 0.5x 2.0cm subserosal fibroid anteriorly (Figure 2B). The uterus was adhered to the sigmoid colon, and the Pouch of Douglas was obliterated. The tubes, ovaries and adjacent structures were normal. There were no complications during intraoperatively and postoperatively.

Histopathological examination of the uterus and ovaries confirmed leiomyomata with no signs of endometrial hyperplasia, malignancy, or extra-endometrial gland deposits. Meanwhile, the excised umbilical nodule tissue revealed fibro-adipose connective tissue with multiple foci of endometrial glandular tubes and surrounding endometrial stroma with a clear surgical margin. The findings were consistent with the diagnosis of umbilical endometriosis.

Her final diagnosis was primary umbilical endometriosis with Stage 3 endometriosis based on the patient's history, clinical and surgical findings. The patient was discharged well on day three of operation and has been well since then with no signs of recurrence.

## DISCUSSION

Cutaneous endometriosis primarily affects women in their reproductive age. It accounts for 0.5-1% of all ectopic sites of endometriosis.<sup>4</sup> The mean age is 35.1-37.7 years of age. The commonest site is the umbilicus, even though other areas such as arm, groin and caesarean section scar has been reported.<sup>2,5</sup> It usually presents as a papule or nodule, which is firm, bluish in colour, and measures less than 2cm in diameter.<sup>5</sup>

UE can be classified as primary or secondary based on the patient's surgical history. In primary umbilical endometriosis, the deposits are spontaneous compared to the secondary, which is associated with prior abdominal surgery.<sup>6</sup> UE patients usually present with dysmenorrhea, cyclical pain at the umbilicus, bleeding, and swelling associated with the menstrual cycle.<sup>6,7</sup>

Numerous theories are proposed to understand the pathogenesis of primary and secondary cutaneous

endometriosis. These include the embryonal rest theory, retrograde menstruation theory, the coelomic metaplasia theory, and migratory pathogenesis theory cellular proliferation. It is postulated that the primary UE occurs as a result of endometriosis seeding. The seeding happens via bloodstream or lymphatics drainage where the umbilicus act as a physiologic scar.<sup>5,8</sup>

As in our patient, the diagnosis is usually made based on the clinical history and physical examination.<sup>9</sup> Abdominal nodule and dysmenorrhea were the commonest presentations reported by Victory R et al.<sup>5</sup>

Blood investigations and imaging modalities such as ultrasound and MRI can be helpful when the diagnosis is in doubt or to evaluate the differential diagnosis of umbilical lesions and the neighbouring structures.<sup>3</sup> Most reports concluded that imaging investigations were not superior to physical examination.<sup>3</sup> CA 125 may be raised but may not be conclusive.<sup>9</sup> However, histopathological examination (HPE) remains the gold standard for definitive diagnosis.<sup>10</sup> Fine needle cytology is not recommended as it has a low yield for diagnosis and can cause potential contamination linked to the puncture site.<sup>3</sup>

Many publications do not recommend a laparoscopy investigation to look for concurrent pelvic endometriosis. The reason is that only 0-25% of patients with UE have concurrent pelvic endometriosis.<sup>5</sup> Our patient's case has demonstrated that there was also pelvic endometriosis despite having primary umbilical endometriosis.

Currently, there is no standard guideline in managing UE. Nevertheless, reported cases of UE have suggested surgical excision as the definitive treatment.<sup>3,7</sup> Some reports have recommended medical treatment consisting of oral contraception pills and gonadotropin-releasing hormone to prevent recurrence after surgery.<sup>3</sup> Though medical treatment is ineffective as primary treatment, for women who are near to menopause, it could be a reasonable option.

In our patient, medical treatment with oral Dienogest was chosen because of the patient's age and choice of treatment after an informed decision discussion. However, she continued to have severe dysmenorrhea despite the therapy; hence TAHBSO and excision of the umbilical nodule were offered. Surgical excision of the nodule requires a wide surgical margin of at least 1cm to avoid recurrence and malignant transformation.<sup>10</sup>

Countless differential diagnoses can mimic UE. It can be rather challenging for untrained eyes to distinguish between these lesions. The challenge is especially true when patients present in an atypical presentation not related to menses. Differential diagnosis of UE includes keloid, pyogenic

granuloma, basal cell carcinoma, hemangioma and Sister's Mary Joseph Nodule (cutaneous metastatic carcinoma).<sup>3</sup> Hence, a high index of suspicion consisting of thorough history taking, physical examination and sometimes imaging modalities are needed.

### CONCLUSIONS

In conclusion, our case highlights the possibility of cutaneous endometriosis, which needs to be considered when evaluating an umbilical mass with bleeding and cyclical pain during menses. Despite being uncommon, it can affect the quality of life of patients. Primary care physicians should have a high clinical suspicion for timely referral and management.

### CONFLICT OF INTEREST

The authors declare that they have no conflict of interest regarding the publication of this case report.

### FUNDING

This case report has received financial assistance from institutional grant RIGS IRF19-020-0020

### REFERENCES

1. Osayande AS, Mehulic S. Diagnosis and initial management of dysmenorrhea. *Am Fam Physician* 2014; 89(5): 341-6.
2. Seung-Hee Loh, Bark-Lynn Lew W-YS. Primary cutaneous endometriosis of umbilicus. *Ann Dermatol*. 2017; 29(5): 621-5.
3. Capasso L, Sciascia V, Loiacco G, Guida G, Iarrobino F, Di Lillo C, et al. Primary subcutaneous umbilical endometriosis: case report and review of the literature. *Case Rep Surg*. 2020; 2020: 1-5.
4. Loh SH, Lew BL Sim WY. Primary cutaneous endometriosis of umbilicus. *Ann Dermatol*. 2017; 29(5): 621-5.
5. Victory R, Diamond MP, Johns DA. Villar's nodule: a case report and systematic literature review of endometriosis external of the umbilicus. *J Minim Invasive Gynecol*. 2007; 14: 23-32.
6. Efremidou EI, Kouklakis G, Mitrakas A, Liratzopoulos N, Polychronidis ACH. Primary umbilical endometrioma: a rare cause of spontaneous abdominal wall endometriosis. 2012; 5: 999-1002. *Int J Gen Med*. 2012; 5: 999-1002.
7. Minaidou E, Polymeris A, Vassiliou J, Kondi-Paphiti A, Karoutsou E, Katafygiotis P, et al. Primary umbilical endometriosis: case report and literature review. *Clin Exp Obstet Gynecol*. 2012; 39(4): 562-4.
8. Malik R, Sharma P. Menstruating umbilicus! a rare case report of primary umbilical endometriosis with review of literature. *Int J Reprod Contraception, Obstet Gynecol*. 2016; 5(7): 2453-6.
9. Sara A. Al-Quorain, Tariq A A-Yahya. Primary umbilical endometriosis: case report with literature review. *Saudi J Med Med Sci*. 2017; 5(1): 74-6.
10. Marras S, Pluchino N, Petignat P, Wenger JM, Ris F, Buchs NC, et al. Abdominal wall endometriosis: an 11-year retrospective observational cohort study. *Eur J Obstet Gynecol Reprod Biol X*. 2019; 4: 4-8.