

A rare case of pigmented seborrhoeic keratosis of scalp

Arosish Dash, MBBS

Department of General Surgery, Saveetha Medical College and Hospital, Saveetha Institute of Medical and Technical Sciences (SIMATS), Saveetha University, Thandalam, Chennai, Tamil Nadu, India

ABSTRACT

Seborrheic keratosis (SK) is a prevalent hyperkeratotic dermatological condition characterized by benign proliferation of epidermal keratinocytes, typically occurring in the middle to advanced stages of life. While the trunk is the primary site for lesions, they can also manifest on the extremities, face, and scalp. Although SK is typically benign, there can be morphological overlap with malignant skin lesions, necessitating meticulous differentiation for an accurate diagnosis. This case report describes a 63-year-old male presenting with scalp swelling that was, initially suspected to be malignant. However, histopathological examination revealed pigmented seborrheic keratosis, prompting the need for a comprehensive management approach. Surgical excision with a rotational flap cover was performed successfully, highlighting the importance of precise diagnosis and management in addressing cutaneous lesions. The exact etiology of SK remains elusive, with potential genetic associations implicated in its pathogenesis. Although treatment may not always be necessary, various modalities are available for lesion removal or symptom management, with surgical intervention reserved for cases exhibiting signs of malignancy. Clinicians should be aware of the atypical presentations of SK and, emphasize the need for a multidisciplinary approach involving dermatologists, pathologists, and surgeons for optimal outcomes.

INTRODUCTION

Seborrheic keratosis is a prevalent hyperkeratotic condition affecting the epidermis and, typically manifesting in the middle or advanced stages of life. The trunk is the predominant location for lesions; however, they can also be observed on the extremities, face, and scalp¹. Seborrheic keratosis, also known as seborrheic warts or senile warts, typically presents as tiny and fibrous lesions. The occurrence of huge isolated lesions is infrequent. Both males and females are equally impacted, and a majority of patients exhibit numerous lesions that are frequently dispersed in a symmetrical manner.

Although seborrheic keratoses are typically benign tumors characterized by distinct features, there can occasionally be morphological overlap with other malignant skin lesions, highlighting the importance of meticulous differentiation. Recognizing these nuances is vital for accurately distinguishing seborrheic keratoses from both benign and malignant skin tumors. While treatment may not always be imperative owing to its benign nature, a significant proportion of patients still opt for various forms of

intervention, underscoring the significance of precise diagnosis and considering patient preferences in the management of these lesions.

The precise etiology of seborrheic keratosis remains unclear. Aging, physical stress, irritation, infection, and host responses have been identified as predisposing variables². The main risk factor for SK is UV radiation exposure. The otolaryngological literature has not sufficiently clarified the inclusion of seborrheic keratosis as a potential diagnosis for nasal lesions. In this instance, we describe a situation in which a single large, lesion damages the scalp area.

CASE

A 63-year-old man presented to the outpatient department with a complaint of swelling on his scalp that had persisted for the past year. Given the duration and nature of the swelling, clinical suspicion was inclined towards a potentially malignant lesion, particularly melanoma. To clarify the diagnosis and plan appropriate management, edge-wedge biopsy was promptly performed. Subsequent histopathological examination yielded unexpected results, and the lesion was identified as pigmented seborrheic keratosis, a benign condition. This diagnosis prompted further consideration of the patient's management plan. Although benign, seborrheic keratosis lesions can sometimes exhibit atypical features that raise concerns regarding malignancy. Therefore, a comprehensive approach was adopted to ensure an accurate diagnosis and appropriate management.

In light of the histopathological findings, the decision was made to proceed with excision biopsy along with a rotational flap cover. This surgical intervention aimed not only to address the patient's cosmetic concerns but also to definitively manage the lesion and prevent potential complications or recurrence. The procedure was executed without complications and the patient's postoperative period was uneventful, with careful monitoring revealing healthy wound healing and flap integrity.

Histopathological examination of the excised tissue provided further insights into the nature of the lesion. Seborrheic keratosis, a common benign skin growth, arises from the proliferation of immature keratinocytes. This proliferation leads to the formation of well-demarcated, round or oval, flat-shaped macules on the skin surface. While they are typically slow-growing, these lesions can increase in thickness over time and rarely resolve spontaneously.

This article was accepted: 07 August 2024

Corresponding Author: Rahul Raj Chennam Lakshmi Kumar

Email: rahul808@gmail.com

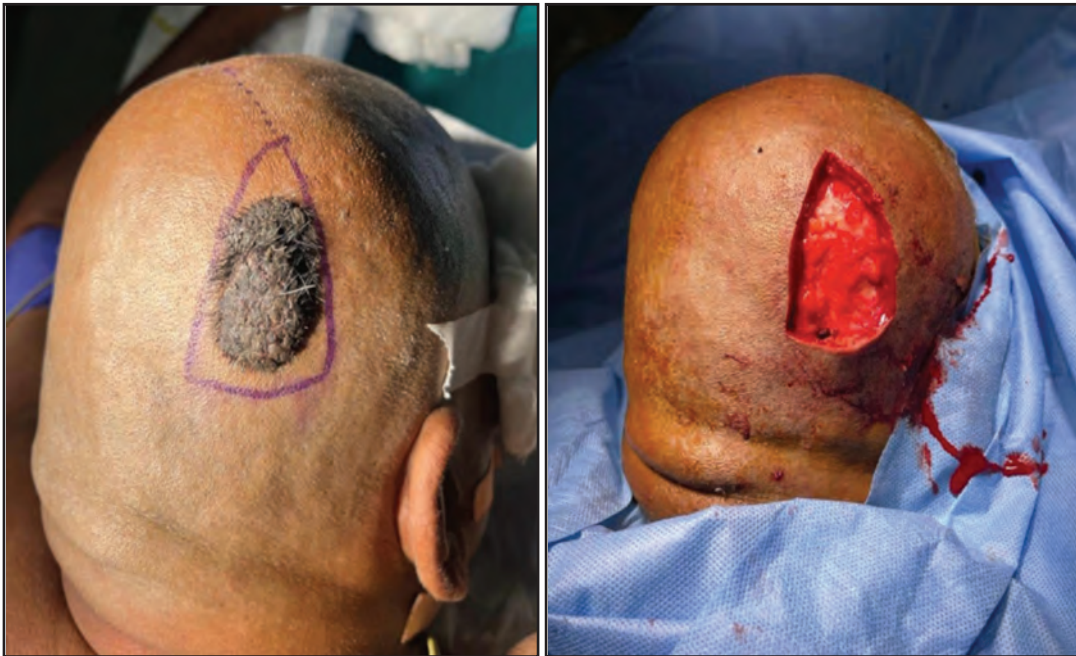

Fig. 1: Intra operative before excision and post excision

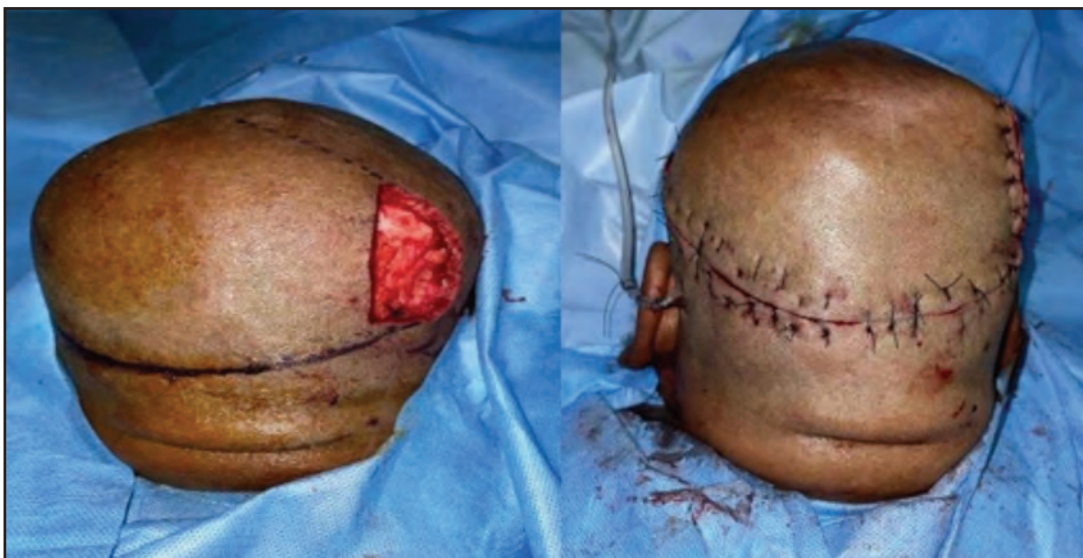

Fig. 2: Intra operative rotational flap cover

However, the exact pathogenesis of seborrheic keratosis remains incompletely understood. However, emerging evidence suggests a genetic predisposition, with mutations in the fibroblast growth factor receptor-3 (FGFR3) and PIK3CA oncogenes implicated in its development. Specifically, activating mutations in FGFR3 are common in sporadic cases of seborrheic keratosis, driving the proliferation of keratinocytes and contributing to tumor growth. Moreover, various subtypes of seborrheic keratosis exist, each exhibiting distinct histopathological features including hyperkeratosis, acanthosis, pseudocysts, hyperpigmentation, inflammation, and dyskeratosis.

Histopathological examination of the excised lesion revealed characteristic features consistent with those of seborrheic keratosis. Microscopic evaluation revealed epidermal hyperkeratosis, acanthosis, and pseudohorny cysts with cytoplasmic pigmentation. Additionally, sparse lymphocytic infiltration was observed in the underlying dermis, suggesting a mild inflammatory response to the lesion.

Despite its benign nature, seborrheic keratosis occasionally presents with atypical features that mimic malignant lesions, warranting careful clinical evaluation and histopathological confirmation. Given the high prevalence of seborrheic keratosis, distinguishing between benign and malignant

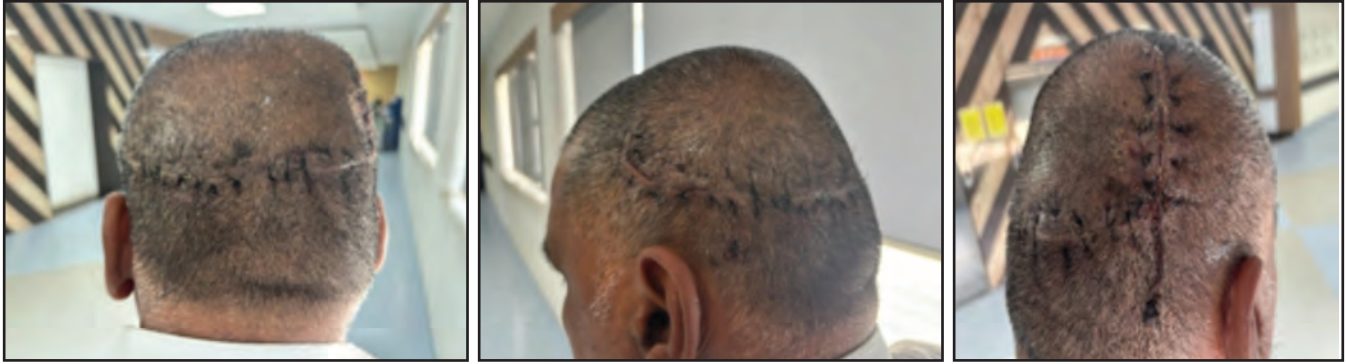

Fig. 3: Post operative scar quality

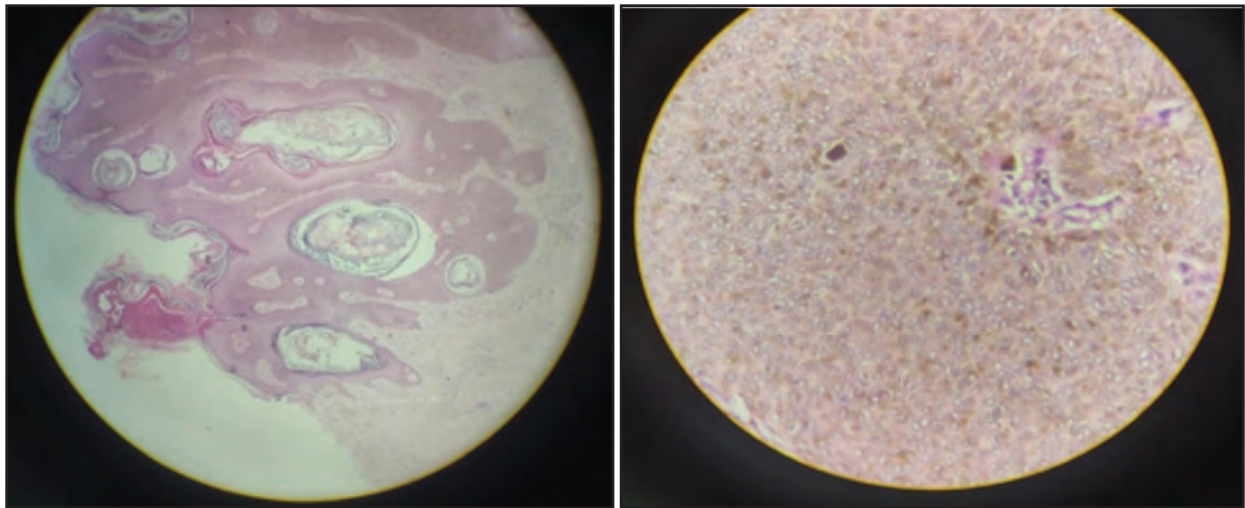


Fig. 4: Histopathology examination images. The above HPE section shows skin with acanthosis, papillomatosis with horn cysts (both true and pseudo cysts), and many keratinocytes showing pigmentation. Granulomas or atypia were noted. Impression suggestive of pigmented seborrhoeic keratosis

lesions is crucial for guiding appropriate management decisions. Biopsy remains the gold standard for definitive diagnosis, particularly for lesions with suspicious clinical features or an inadequate response to conservative management.

The present case emphasizes the importance of a comprehensive approach for the diagnosis and management of cutaneous lesions. Although benign in nature, seborrhoeic keratosis can pose diagnostic challenges, necessitating careful clinical evaluation and histopathological confirmation. Through meticulous assessment and appropriate intervention, clinicians can ensure optimal outcomes in patients presenting with cutaneous lesions.

DISCUSSION

Seborrhoeic keratoses are lesions characterized by their flat, verrucous, polypoid, or pedunculated nature. These lesions typically have a size range of 0.5 cm to 1 cm and exhibit a range of colors, spanning from tan-brown to black. Most of the lesions did not show any symptoms and had clearly defined borders.

Seborrhoeic keratosis is characterized by uncontrolled growth of immature keratinocytes, leading to the formation of distinct, round or oval, flat-shaped lesions. Usually characterized by gradual growth, these lesions have the tendency to thicken over time and seldom resolve on their own. The aforementioned ailment arises from the non-malignant proliferation of epidermal keratinocytes, wherein a potential hereditary factor is believed to play a role in the formation of multiple lesions. However, the precise mechanism of familial inheritance remains unclear. Although there is still limited understanding of its exact etiology, there are probable associations between fibroblast growth factor receptor 3 (FGFR3) and PIK3CA oncogenes. Mutations in FGFR3, a receptor for tyrosine kinase, are frequently observed in sporadic seborrhoeic keratosis, and are believed to be responsible for the proliferation of these non-malignant neoplasms. Seborrhoeic keratosis consists of different subtypes including, acanthotic, hyperkeratotic, clonal, adenoid, irritable, and melanoacanthoma. Pathological lesions sometimes show characteristics of multiple subtypes. The aforementioned intricacy highlights the necessity for thorough evaluation and precise identification in the management of these lesions.

The Leser-Trélat sign refers to the abrupt occurrence of seborrheic keratoses or an escalation in the quantity of lesions, which can potentially be linked to an underlying internal cancer, typically adenocarcinoma affecting the stomach, colon, or breast³. Acrochordon, verruca vulgaris, follicular adnexal tumors, melanocytic tumors, and squamous or basal cell carcinoma are among the clinical differential diagnoses that should be considered. Hence, performing a histopathological investigation is crucial to verify the clinical observations. Seborrheic keratosis may need to be removed due to cosmetic preferences, to address symptoms such as itching, bleeding, and inflammation, or to confirm clinical findings. Available treatment modalities include cryosurgery, electrodesiccation, shave excision, carbon dioxide laser vaporization, and surgical removal. Topical corticosteroids can be employed to alleviate symptoms of inflamed lesions^{4,5}. Surgical interventions should be limited to cases in which lesions exhibit indications of malignancy. To the best of our knowledge, there have been fewer earlier reports of seborrheic keratosis occurring on the scalp. Medical professionals should be aware of the atypical positioning of lesions. No literature suggests that seborrheic keratosis of the scalp can undergo malignant transformation. It is a primarily benign condition.⁶ Our patient had no risk of malignant transformation. The various treatment options available for SK include cryotherapy, electrodesiccation, curettage, ablative laser treatment, shave biopsy and topical agents.⁷ While there is great interest from both patients and providers in a topical non-invasive treatment for SK, no effective topical therapeutic agent has been developed, and this remains an area of unmet need.⁸ No adjuvant therapy is required for seborrheic keratosis has been warranted. However, there is no available literature to justify this.

The above HPE section shows skin with acanthosis, papillomatosis with horn cysts (both true and pseudo cysts), and many keratinocytes showing pigmentation. Granulomas or atypia were noted. Impression suggestive of pigmented seborrhoeic keratosis.

CONCLUSION

In conclusion, seborrheic keratosis represents a common dermatological condition characterized by the benign proliferation of epidermal keratinocytes, resulting in well-defined, often pigmented lesions. Histopathological examination is essential for accurate diagnosis. In our patient, we performed excision and biopsy with a rotational flap cover. Postoperatively, the patient recovered well without any complications, and the postoperative scar was good. The postoperative histopathology report was the same as the preoperative report, thereby confirming it a case of pigmented seborrheic keratosis of the scalp.

REFERENCES

1. King R, Page RN, Googe PB. Desmoplastic seborrheic keratosis. *Am J Dermatopathol* 2003; 25: 210-4.
2. Anderson PJ, Zuk JA, Rao GS, Berry RB. Squamous cell carcinoma arising within seborrheic keratosis. *Plast Reconstr Surg* 1998; 102: 453-5.
3. Kyrmizakis DE, Vrentzos EE, Papadakis CE, Chroniaris NE, Bizakis JG, Amanakis ZE. Seborrheic keratosis of the auricle: report of an unusual case. *Ear Nose Throat J* 2002; 81: 107-9.
4. Thomas I, Kihiczak NI, Rothenberg J, Ahmed S, Schwartz RA. Melanoma within the seborrheic keratosis. *Dermatol Surg* 2004; 30(4 Pt 1): 559-61.
5. Lambert PR, Fechner RE, Hatcher CP. Seborrheic keratosis of the ear canal. *Otolaryngol Head Neck Surg* 1987; 96:198-201.
6. Barthelmann S, Butsch F, Lang BM, Stege H, Großmann B, Schepler H, Grabbe S. Seborrheic keratosis. *J Dtsch Dermatol Ges*. 2023; 21(3): 265-277. [PubMed]
7. Greco MJ, Bhutta BS. Seborrheic Keratosis. [Updated 2024 May 6]. In: StatPearls [Internet]. Treasure Island (FL): StatPearls Publishing; 2024 Jan-.
8. Jackson JM, Alexis A, Berman B, Berson DS, Taylor S, Weiss JS. Current Understanding of Seborrheic Keratosis: Prevalence, Etiology, Clinical Presentation, Diagnosis, and Management. *J Drugs Dermatol*. 2015; 14(10): 1119-25.