

Comparison between Single Incision Laparoscopic Appendectomy (SILA) and Multi Port Laparoscopic Surgery (MPLA) in paediatric appendectomy patients

Yudi Pratama, MD¹, Andi Dwihantoro, MD¹, Gunadi, PhD¹, Yofizal Idham Ahmad, MD¹, Eko Purnomo, PhD²

¹Pediatric Surgery Division, Department of Surgery, Faculty of Medicine, Public Health and Nursing, Universitas Gadjah Mada/ Dr. Sardjito Hospital, Yogyakarta, Indonesia, ²Pediatric Surgery Division, Department of Surgery, Faculty of Medicine, Public Health and Nursing, Universitas Gadjah Mada, Academic Hospital, Yogyakarta, Indonesia

ABSTRACT

Introduction: Single Incision Laparoscopic Appendectomy (SILA) and Multiport Laparoscopic Appendectomy (MPLA) are both established techniques for appendectomy, yet their differences in terms of aesthetics, operative wounds, and complications like wound dehiscence remain under study. This research compares the two approaches with a focus on minimizing surgical trauma and reducing infection risks.

Materials and Methods: A retrospective study was conducted involving 49 patients, with 26 undergoing SILA and 23 undergoing MPLA across two hospitals in Yogyakarta. Patient demographics, appendicitis grade, length of stay (LOS), operative time, and postoperative complications, including dehiscence, were analyzed using SPSS.

Results: Dehiscence was evaluated through outpatient follow-up based on wound leakage, while other complications were documented accordingly. The cohort comprised 17 female and 32 male patients (1:2 ratio), with no significant association between gender and appendicitis type ($p=0.16$). The most common appendicitis grade was grade 1 (36%), followed by grade 2 (34.7%), with chronic appendicitis being the least common (8.2%). was observed in 12.2% of cases, with 87.8% of wounds healing without issue. No significant difference in complication rates was found between SILA and MPLA techniques ($p=0.876$). LOS ($p=0.523$) and operative time ($p=0.185$) also showed no statistically significant differences.

Conclusion: Both SILA and MPLA techniques for appendectomy offer comparable safety profiles, with no significant differences in complications, LOS, or operative time. SILA, however, may offer superior cosmetic outcomes due to fewer incisions.

KEYWORDS:

Laparoscopy, Single Incision Laparoscopic Appendectomy (SILA), Multiport Laparoscopic Appendectomy (MPLA), appendectomy, dehiscence, surgical Outcomes

INTRODUCTION

Appendicitis is one of the most frequent causes of surgical emergencies, and is one of the most frequent causes of abdominal pain in the pediatric population (Gadiparthi and Waseem, 2023). Inflammation of the appendix can be caused by various etiologies, such as fecolith, appendicolith, and lymphoid hyperplasia. In the pediatric population, the most common etiology of appendicitis is lymphoid hyperplasia.¹

Obstruction of the appendix lumen by any mechanism/etiology can cause bacterial overgrowth which causes acute inflammation and abscess formation. A previous study found that patients with perforated appendicitis had a much higher number of bacterial phyla compared with patients with uncomplicated appendicitis. These findings suggest that the severity and progression of appendicitis may be associated with an increase in the number of bacterial species.²

Obstruction of the appendix lumen will also cause an increase in intra-lumen pressure, which will cause distension of the appendix and disrupt blood perfusion to the appendix wall. As a result, ischemia of the appendix wall will occur. If this condition is left untreated, perforation can occur in the appendix wall.³

Antibiotics is still the preferred initial treatment to treat cases of appendicitis that have not yet perforated. For perforated appendicitis, antibiotics plus appendectomy surgery is the treatment of choice. Currently, most appendectomy operations are performed laparoscopically. The main factor that determines whether an appendectomy surgery will be performed by open surgery or laparoscopic is the preference or expertise of the surgeon. Generally, a laparoscopic approach is preferred if surgical expertise and equipment are available.³

Single Incision Laparoscopic Appendectomy (SILA) and Multiport Laparoscopic Appendectomy (MPLA) are both established techniques for appendectomy, yet their differences in terms of aesthetics, operative wounds, and complications like wound dehiscence remain under study. This research compares the two approaches with a focus on minimizing surgical trauma and reducing infection risks.

Table I: Baseline Characteristics of the Patients (N=49)

Characteristic	Procedure Group		N (%)
	SILA	MPLA	
Gender			
• Male	13 patients	4 patients	34.69%
• Female	13 patients	19 patients	65.30%
Mean age	10.73 y.o.	11.43 y.o.	
Mean body weight	39.63 kg	38.54 kg	
Post-op diagnosis			
• Grade 1 appendicitis	9 cases	9 cases	36.73%
• Grade 2 appendicitis	11 cases	6 cases	34.69%
• Grade 3 appendicitis	1 case	0 case	2.04%
• Perforated appendicitis	2 cases	3 cases	10.20%
• Acute exacerbation on chronic appendicitis	3 cases	1 case	8.16%
• Chronic appendicitis	0 case	4 cases	8.16%

Table II: Comparison of Outcome between SILA and MPLA

Outcomes	SILA	MPLA	P value
Mean operation duration	96.92 min	85.43 min	0.185
Length of stay post-operation	3.13 days	2.78 days	0.523
Dehiscence complication	3 cases	3 cases	0.876

Figures 1–4 illustrate the comparisons in age, body weight, operative duration, and length of stay between the two groups.

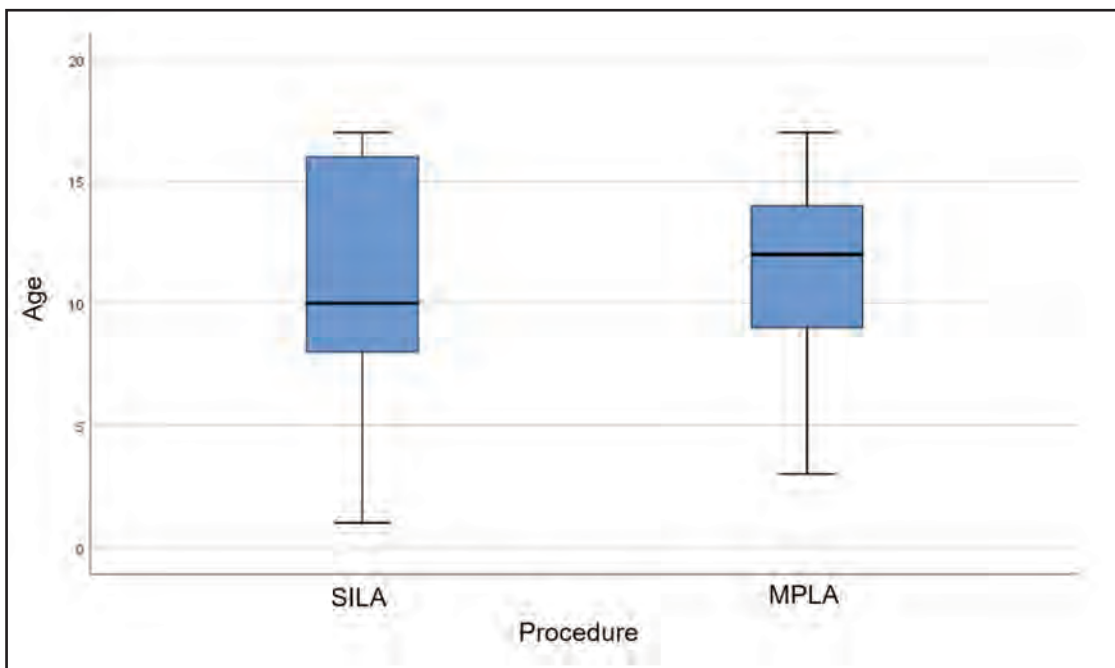


Fig. 1: Plot graphic for patients’ age between SILA vs MPLA procedure

MATERIALS AND METHODS

Study Design and Patients

This study is a retrospective cohort study was conducted involving pediatric patients with appendicitis that undergone SILA or MPLA procedure across two hospitals in Yogyakarta from 2023 to 2024. This study aimed to evaluating and comparing the outcomes of SILA and MPLA procedures in those pediatric appendicitis cases.

Data Collection

We evaluate patient demographics, appendicitis grade, length of stay (LOS), operative time, and postoperative complications, including dehiscence. Dehiscence was evaluated through outpatient follow-up based on wound leakage, while other complications were documented accordingly.

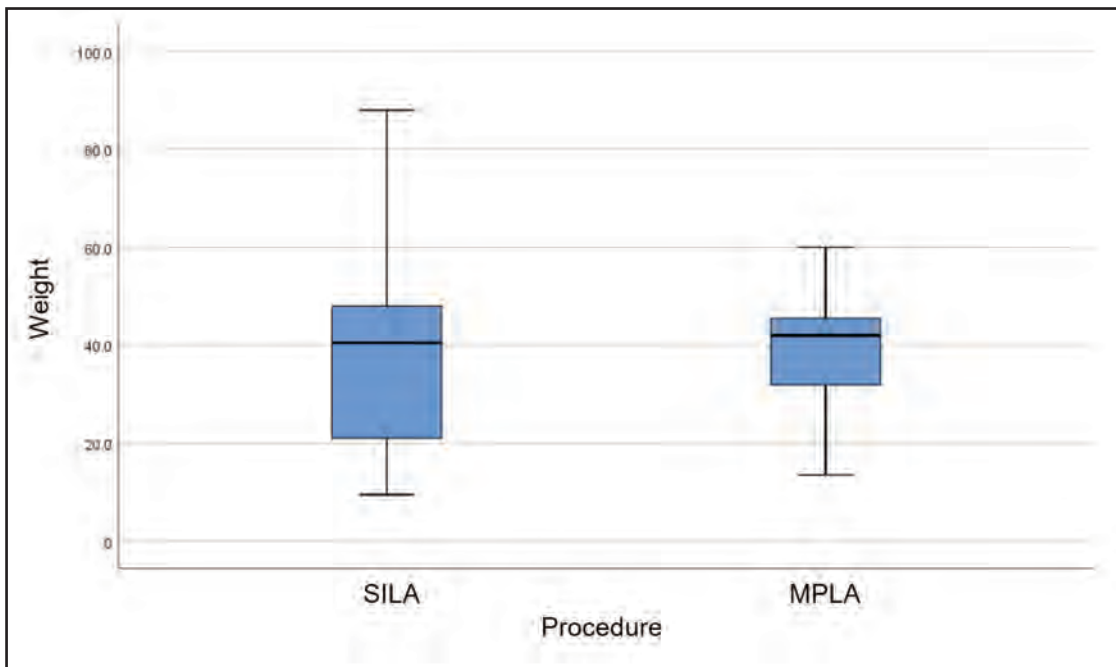


Fig. 2: Plot graphic for patients' body weight between SILA vs MPLA procedure

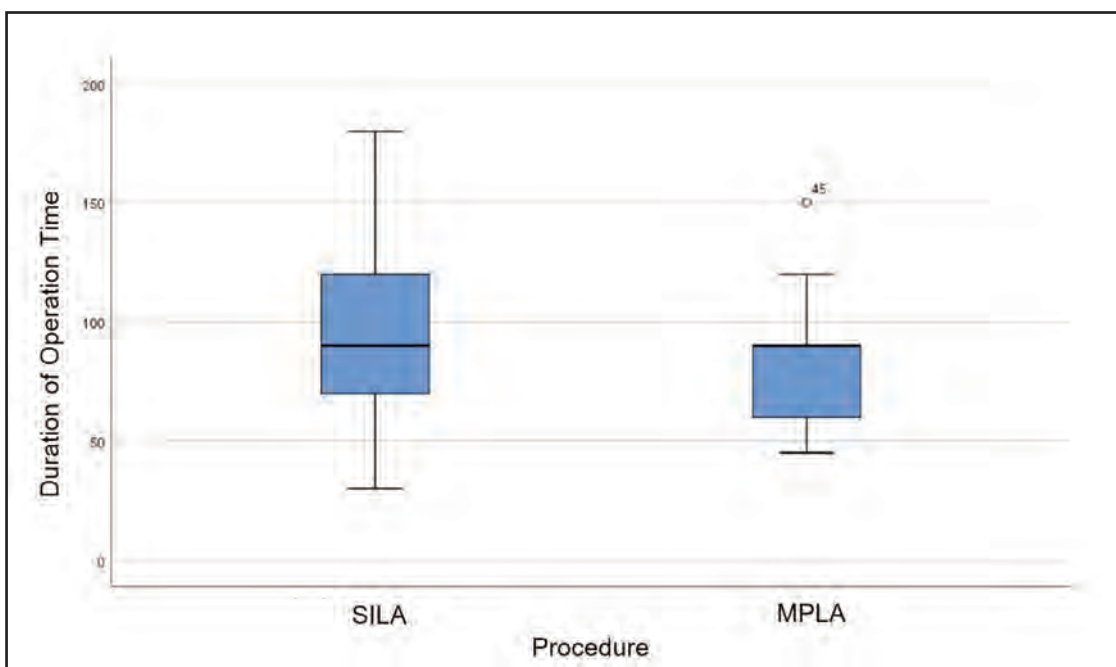


Fig. 3: Plot graphic for operation duration between SILS vs MPLA procedure

Statistical Analysis

The data collected was analyzed using SPSS. We did independent T test to see is there any significant differences of the data between SILA and MPLA procedures. p-value of <0.05 was considered as significant.

RESULTS

There are 49 patients involved in this study, with 26 undergoing SILA and 23 undergoing MPLA across two hospitals in Yogyakarta (Table I). The cohort comprised 17 female and 32 male patients (1:2 ratio), with no significant association between gender and appendicitis type (p=0.16). The most common appendicitis grade was grade 1 (36%), followed by grade 2 (34.7%), with chronic appendicitis being

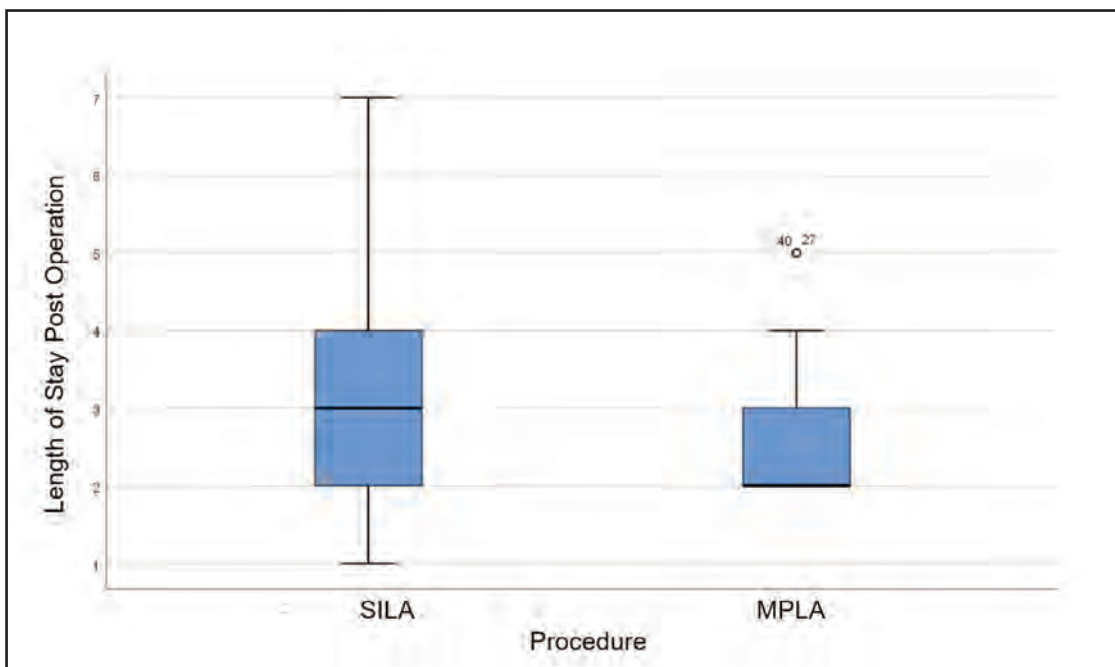


Fig. 4: Plot graphic for patients' length of stay between SILS vs MPLA procedure

the least common (8.2%). Dehiscence was observed in 12.2% of cases, with 87.8% of wounds healing without issue. No significant difference in complication rates was found between SILA and MPLA techniques ($p=0.876$). LOS ($p=0.523$) and operative time ($p=0.185$) also showed no statistically significant differences (Table II).

DISCUSSION

From these data, we can see that there's no significant differences in complications, length of stay, or operative time between SILA and MPLA. These findings are similar with previous studies, stating that both of SILA and MPLA can offer comparable safety profiles in management of appendicitis.⁴ However, SILA procedure offer better cosmetic outcomes than MPLA because of fewer incisions.⁵

Another study conducted by Liao, 2020⁶ found that the SILA procedure had a shorter average surgical duration of 8 minutes compared to MPLA, but this time difference was not statistically significant ($p = 0.222$). However, this study found that the SILA procedure had better recovery parameters, especially in terms of soft diet intake and post-operative hospitalization ($p < 0.001$).

Research conducted by Chandler and Danielson⁷ found that the SILA procedure was better than MPLA in terms of the need for narcotics use (0.9 doses in SILA vs 1.4 doses in MPLA, $p = 0.01$). However, there were no significant differences regarding complication rates and length of stay.

Another study conducted by Buckley et al⁸ found that there was no significant difference between SILA and MPLA in terms of duration of operation, length of stay, and level of

risk of needing to convert to open appendectomy. Apart from that, there was no significant difference regarding the incidence of complications from SILA and MPLA. These findings are similar to our findings in this study.

Considering that both procedures have equally good safety profiles, without any significant differences between the two, SILA could be a more favorable procedure choice than MPLA, because SILA has better cosmetic outcomes than MPLA.

CONCLUSION

Both SILA and MPLA techniques for appendectomy offer comparable safety profiles, with no significant differences in complications, length of stay, or operative time. SILA, however, may offer superior cosmetic outcomes due to fewer incisions.

CONFLICT OF INTEREST

The authors declare no conflicts of interest.

ACKNOWLEDGEMENTS

The authors would like to thank the participants of the study.

FUNDING

The authors received no external funding.

REFERENCES

1. Lotfollahzadeh S, Lopez RA, Deppen JG. Appendicitis. StatPearls. Treasure Island (FL): StatPearls Publishing Copyright © 2025, StatPearls Publishing LLC.; 2025.

2. Bhangu A, Søreide K, Di Saverio S, Assarsson JH, Drake FT. Acute appendicitis: modern understanding of pathogenesis, diagnosis, and management. *Lancet* 2015; 386(10000): 1278-87.
3. Gadiparthi R, Waseem M. Pediatric Appendicitis. StatPearls. Treasure Island (FL): StatPearls Publishing Copyright © 2025, StatPearls Publishing LLC.; 2025.
4. Zaman S, Mohamedahmed AYY, Stonelake S, Srinivasan A, Sillah AK, Hajibandeh S, et al. Single-port laparoscopic appendectomy versus conventional three-port approach for acute appendicitis in children: a systematic review and meta-analysis. *Pediatr Surg Int* 2021; 37(1): 119-27.
5. Han Y, Yuan H, Li S, Wang WF. Single-incision versus conventional three-port laparoscopic appendectomy for acute appendicitis: A meta-analysis of randomized controlled trials. *Asian J Surg* 2024; 47(2): 864-73.
6. Liao YT, Lai PS, Hou YZ, Wu CY, Chou TH, Liang JT. Is single-incision laparoscopic appendectomy suitable for complicated appendicitis? A comparative analysis with standard multiport laparoscopic appendectomy. *Asian J Surg* 2020; 43(1): 282-9.
7. Chandler NM, Danielson PD. Single-incision laparoscopic appendectomy vs multiport laparoscopic appendectomy in children: a retrospective comparison. *Journal of Pediatric Surgery* 2010; 45(11): 2186-90.
8. Buckley FP, 3rd, Vassaur H, Monsivais S, Jupiter D, Watson R, Eckford J. Single-incision laparoscopic appendectomy versus traditional three-port laparoscopic appendectomy: an analysis of outcomes at a single institution. *Surg Endosc* 2014; 28(2): 626-30.